

Clinical trial

Topical epidermal growth factor for the improvement of acne lesions: a randomized, double-blinded, placebo-controlled, split-face trial

Hyun Kyu Kim, MD, In Kwon Yeo, MD, Kapsok Li, MD, PhD, Beom Joon Kim, MD, PhD, Myeung Nam Kim, MD, PhD, and Chang Kwun Hong, MD, PhD

Department of Dermatology, Chung-Ang University College of Medicine, Seoul, Korea

Correspondence

Beom Joon Kim, MD, PhD
Department of Dermatology
Chung-Ang University Hospital
224-1 Heukseok-dong
Dongjak-gu, Seoul 156-755
South Korea
E-mail: beomjoon@unitel.co.kr

Abstract

Acne is one of the most common adverse events associated with the use of anticancer agents, such as epidermal growth factor receptor (EGFR) inhibitors. Based on data from several previous reports, we predicted that topical application of EGF could improve acne vulgaris. To evaluate the clinical efficacy and safety of topical recombinant human EGF (rhEGF) cream for the treatment of facial acne vulgaris. Twenty Korean adults with mild to moderate acne vulgaris applied topical rhEGF cream on one half of the face and a vehicle cream on the other half twice daily for six weeks. Clinical assessments were conducted at baseline, two, four, and six weeks. Two assessment methods were applied: inflammatory and non-inflammatory acne lesion counts and acne severity score by investigator's global assessment. Skin sebum output level and hydration level were also measured at each visit. All volunteers completed the study. At the final visit, inflammatory acne lesions were reduced by 33.5% on the rhEGF-applied side. Non-inflammatory acne lesions also decreased by 25.4%, whereas the lesions on the control side increased. The majority of patients demonstrated improvement on the side of the face where rhEGF cream was applied. Sebum output decreased on the rhEGF side, and skin hydration level increased on both sides. No severe side effects were observed during the study. Topical rhEGF seems to be an effective and safe adjuvant treatment option for mild to moderate acne vulgaris.

Introduction

Under physiological conditions, growth factors are integral to the maintenance of cutaneous functions as autocrine and paracrine mitogens.^{1,2} They also mediate the differentiation of a wide variety of epithelial cells such as keratinocytes and participate in the remodeling of extracellular matrix in skin.^{3,4}

Epidermal growth factor (EGF) was discovered in mouse salivary glands in 1962 and was the first growth factor to be described.⁵ It interacts with the EGF receptor (EGFR) on the surfaces of keratinocytes, cells in the hair follicle, and eccrine and sebaceous glands.⁶ EGF is produced by platelets, macrophages, and monocytes, and its primary role is to stimulate epithelial cells to grow across a wound, although it also exhibits effects on fibroblasts and smooth muscle cells.^{7,8} Overexpression of EGFR is demonstrated in various malignancies, including colorectal, breast, ovarian, prostate, and non-small cell lung cancer.^{9,10} Thus, EGFR inhibitors are often used in anticancer therapy.

Acneiform folliculitis is the most frequently and consistently observed adverse event associated with anti-EGFR therapies.¹¹ The exact mechanisms, however, have yet to be elucidated. A previous report demonstrated that EGF augmented the proliferation of hamster sebocytes *in vitro* and suppressed lipogenesis by decreasing intracellular levels of triglycerides.^{12,13} In addition, topical recombinant human EGF (rhEGF) administered to patients with acneiform eruptions resulted in clinical improvement.¹⁴ Based on these results, we predicted that topical rhEGF would also improve lesions of acne vulgaris and reduce sebum production.

In this study, we aimed to evaluate the clinical efficacy and safety of topical rhEGF in treating mild to moderate facial acne vulgaris.

Materials and methods

In this double-blind, placebo-controlled, split-face clinical trial, 20 Korean patients with mild to moderate acne were recruited. The inclusion criteria were adult acne vulgaris patient (between 20

and 50 years old) with a baseline investigator global assessment (IGA) score of 2 or 3. Exclusion criteria were age out of range, severe acne types such as acne conglobata or fulminans, history of any acne treatment in the preceding three months, and previous history of anti-EGFR therapy. The subjects applied topical rhEGF cream on one side of the face and vehicle cream on the other side twice daily for six weeks. The study product, rhEGF cream (Easydew[®]; Daewoong Pharmaceutical, Seoul, Korea), contained 150,000 ng of rhEGF and 15 ml of solvent (0.01 mg/ml) consisting of purified water, stearyl alcohol, tocopheryl acetate, potassium cetyl phosphate, edetate disodium, octyldodecyl myristate, macadamia oil, sodium hyaluronate, butylene glycol, and ceramide 3. The vehicle was a cream base of the same color that did not contain rhEGF. All enrolled patients were instructed to apply a thin layer of the study cream over acne lesions at least five minutes after skin was gently washed, rinsed with water, and patted dry. The subjects were educated not to bathe, shower, or swim for at least five hours after application of the study materials.

Patients were evaluated in clinic at baseline, two, four, and six weeks. The same photographer took photos of subjects with identical camera settings and lighting. Clinical outcomes were assessed by evaluating acne severity with IGA scores at each visit. IGA is calculated based on a four-point scale that is detailed in Table 1.

Non-inflammatory and inflammatory lesions were counted on each visit by the same blinded investigator. Changes in cutaneous sebum output level were evaluated using a sebumeter SM815 (Courage-Khazaka Electronic GmbH, Köln, Germany). Skin hydration levels were also measured with a corneometer CM825 (Courage-Khazaka Electronic GmbH) at each visit.

For statistical analysis, SPSS software version 12.0 (SPSS Inc., Chicago, IL, USA) was used throughout. The Mann–Whitney test was used to compare the two treatment sides and the Wilcoxon signed rank test was used to compare findings before and after treatment. In all cases, statistical significance was accepted for $P < 0.05$.

Results

Twenty patients (six men and 14 women) were initially enrolled, and all subjects completed the entire study

treatment protocol and returned for follow-up visits. Patients ranged in age from 20 to 34 years, with an average age of 25.3 ± 4.5 years.

The inflammatory acne lesion count was significantly reduced with application of topical rhEGF after four weeks (25.4% reduction, $P < 0.05$; Fig. 1). At the final visit, the count was further reduced, for a total reduction of 33.5% ($P < 0.05$). There was no significant decrease in inflammatory lesions on the vehicle side of the face. Significant differences between rhEGF and vehicle sides were found after four weeks of treatment ($P < 0.05$). Non-inflammatory acne lesion counts demonstrated a significant gradual decrease with topical rhEGF application (Fig. 2). At week 6, the mean lesion count of the rhEGF side reduced by 25.2%, whereas the mean count on the vehicle side actually increased. A significant difference in the mean non-inflammatory acne lesion count between two sides was observed after two weeks of treatment ($P < 0.05$).

Mean baseline acne grades for rhEGF and control sides were 2.90 and 2.75, respectively (Fig. 3). On the rhEGF side, the acne severity grade significantly decreased to 2.55

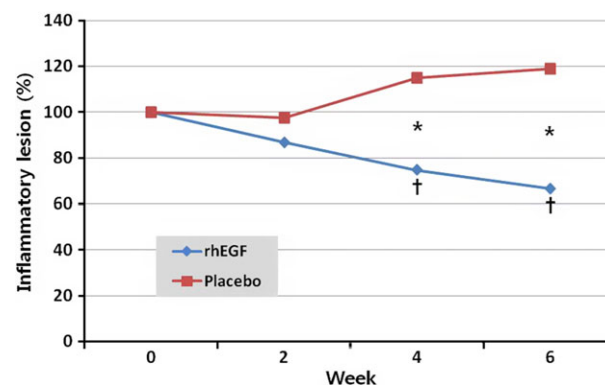


Figure 1 Changes in inflammatory acne lesion counts during the trial period. Acne lesion counts after each treatment are represented as the percentage of pretreatment acne lesions. The mean number of inflammatory lesions decreased significantly after application of rhEGF cream ($*P < 0.05$ vs. placebo, $†P < 0.05$ vs. baseline). rhEGF, recombinant human epidermal growth factor

Table 1 Investigators global assessment score

Score	Description
0	Clear skin with no inflammatory or non-inflammatory lesions
1	Almost clear; rare non-inflammatory lesions with no more than one small inflammatory lesion
2	Mild severity; some non-inflammatory lesions with no more than a few inflammatory lesions (papules/pustules only, no nodular lesions)
3	Moderate severity; up to many non-inflammatory lesions and may have some inflammatory lesions but no more than one small nodular lesion
4	Severe; up to many non-inflammatory and inflammatory lesions but no more than a few nodular lesions

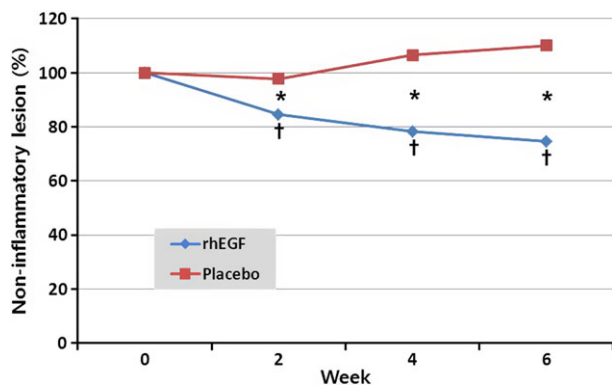


Figure 2 Changes in non-inflammatory acne lesion counts during the trial period. Acne lesion counts after each treatment are represented as the percentage of the number of pretreatment acne lesions. The mean number of non-inflammatory lesions decreased significantly after application of rhEGF cream (* $P < 0.05$ vs. placebo, † $P < 0.05$ vs. baseline). rhEGF, recombinant human epidermal growth factor

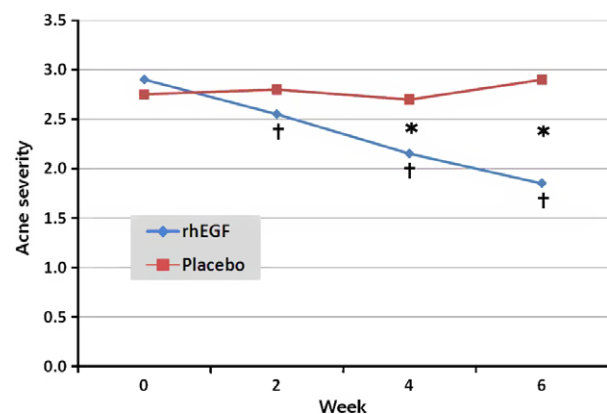


Figure 3 Changes in acne severity with time. Severity score decreased significantly in the rhEGF side, and differences between the two treatment sides were observed at week 4 and week 6 (* $P < 0.05$ vs. placebo, † $P < 0.05$ vs. baseline). rhEGF, recombinant human epidermal growth factor

($P < 0.05$) at week 2, 2.15 ($P < 0.05$) at week 4, and 1.85 ($P < 0.05$) at week 6. On the vehicle side, no significant changes were observed. Statistically significant differences between the two sides were found after four weeks of application. Significant clinical lesion improvements were observed on the rhEGF side (Figs. 4 and 5).

The rhEGF side demonstrated a trend toward an overall decrease in sebum output with the duration of administration, whereas the vehicle side showed a tendency toward slight decrease in sebum output (Fig. 6).

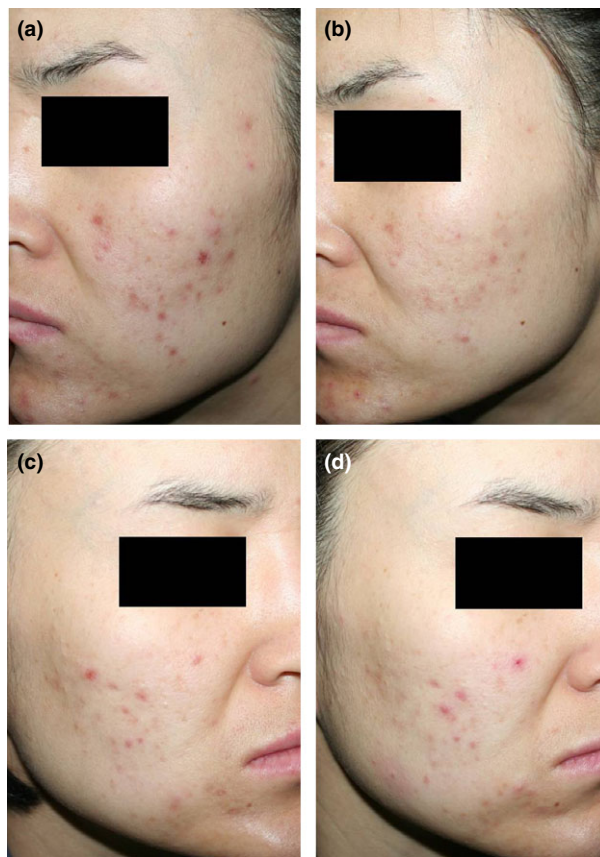


Figure 4 A 33-year-old woman with acne vulgaris. Before and after photos (a, b) 6 weeks application of rhEGF cream; (c, d) 6 weeks application of vehicle cream. Clinical improvement was observed on the rhEGF side. rhEGF, recombinant human epidermal growth factor

Significant differences between the mean values of sebum content on the two sides were found after two weeks of application. Skin hydration levels were significantly increased in both rhEGF and vehicle sides over time (Fig. 7). No differences were observed between the two sides in terms of skin hydration.

No significant adverse effects such as skin irritation or allergic reactions were observed.

Discussion

Acne vulgaris is a common chronic inflammatory disorder of pilosebaceous units. Various factors contribute to the pathogenesis of acne, including increased sebum production, proliferation of follicular keratinocytes, colonization of *Propionibacterium acnes*, and inflammation.¹⁵ Current treatments for acne vulgaris include topical retinoids, benzoyl peroxide, topical and systemic antibiotics, azelaic acid, and systemic isotretinoin.

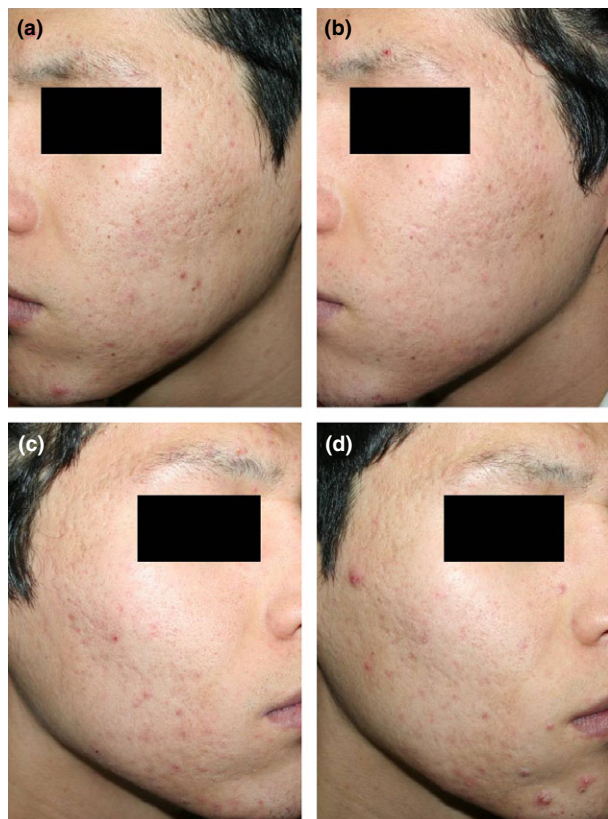


Figure 5 A 23-year-old man with acne vulgaris. Before and after photos (a, b) 6 weeks application of rhEGF cream; (c, d) 6 weeks application of vehicle cream. Clinical improvement was observed on the rhEGF side. rhEGF, recombinant human epidermal growth factor

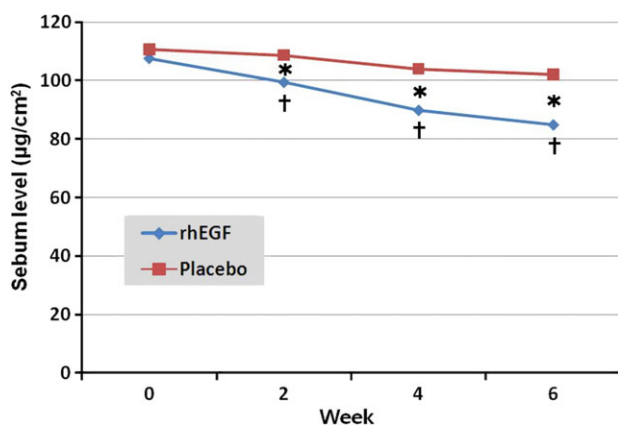


Figure 6 Changes in sebum output level with time. The rhEGF side showed a trend toward an overall decrease in sebum output with the duration of administration (* $P < 0.05$ vs. placebo, † $P < 0.05$ vs. baseline). rhEGF, recombinant human epidermal growth factor

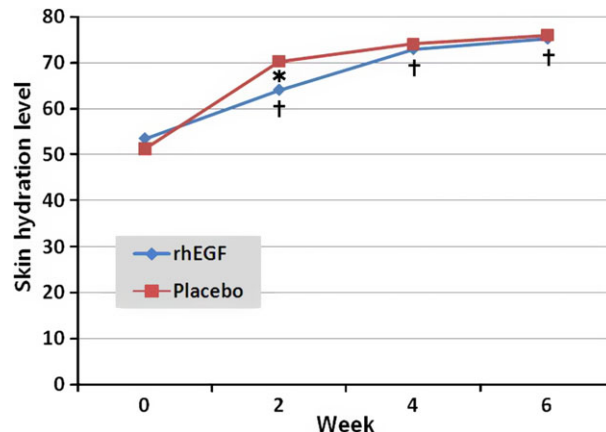


Figure 7 Changes in skin hydration level with time. Both rhEGF and placebo sides showed a significant increase in skin hydration level. No difference between the two sides was observed (* $P < 0.05$ vs. placebo, † $P < 0.05$ vs. baseline). rhEGF, recombinant human epidermal growth factor

Acneiform folliculitis is the earliest and most characteristic side effect of EGFR inhibitor use, and its incidence may occur in upward of 75–100% of cases.^{16,17} Similar to acne vulgaris, EGFR-associated acneiform folliculitis is characterized by clogged pores due to excessive keratinocytes in the follicular infundibulum. The clog traps sebum, which attracts non-pathogenic skin bacteria to the follicle, resulting in inflammation. Most reported treatment options are similar to traditional treatments for acne vulgaris, despite the known etiological differences between the two conditions.¹⁸

Several experimental and clinical studies indicated that growth factors, including EGF, are important for keratinocyte and sebocyte physiology leading to the pathogenesis of acne. Akimoto *et al.* demonstrated that four growth factors (EGF, transforming growth factor- α , basic fibroblast growth factor, and keratinocyte growth factor) inhibited the intracellular accumulation of lipid droplets by suppressing the synthesis of triglycerides in hamster sebocytes, thus they suggested that these growth factors act as suppressors of lipogenesis.¹² The development of sebaceous glands is considered to be modulated by growth factors, as EGFRs exist on sebaceous glands in rats, and EGF has been shown *in vivo* to stimulate sebaceous gland proliferation in the pinna of hamsters.^{19,20} Based on these results, we assumed that EGF has possible anti-acne therapeutic properties.

In the present study, we demonstrated that the topical application of rhEGF was effective for improving both inflammatory and non-inflammatory acne lesions. Significant reductions in inflammatory acne lesion counts were observed on the rhEGF side starting in week 4, and

non-inflammatory lesion counts decreased starting in week 2. The change in acne severity reflects the degree of lesion improvement. Although the treatment side of the face was randomly allocated, the acne severity at baseline was more severe on the rhEGF-treated side compared to the control side. However, the severity grade pattern reversed beginning in week 2. Cutaneous sebum output level decreased on the rhEGF side starting at week 2, and a significant clinical difference was also apparent at that time. Topical EGF likely reduces the level of sebum due to its ability to suppress lipogenesis, which was demonstrated via an *in vivo* study on hamster sebocytes.¹²

While unclear, the proposed therapeutic mechanism of action of the rhEGF on inflammatory acne lesions may occur via an anti-inflammatory effect. Some reports have suggested a possible mechanism for anti-inflammatory effects of EGF. Casacó and colleagues have shown that topical rhEGF is topically efficacious in three experimental models of inflammation.²¹ They explained that interference with arachidonic acid metabolism may play an important role. Pastore *et al.* demonstrated that EGFR activation is involved in the control of chemokine expression in human keratinocytes.²² These data indicate that EGF signaling pathways play a role in skin inflammation by regulating chemokine expression in keratinocytes.

A possible additional role of topical rhEGF in acne is to reduce keratin plugs in follicles. EGFR blockade causes changes in the differentiation and terminal maturation of suprabasal keratinocytes, which results in the formation of keratin plugs in follicles.²³ Thus, reduced keratin plugs may contribute to the improvement of acne lesions. Another possible role for rhEGF is repair of impaired skin barrier function. Moisturizing effects of topical rhEGF may improve barrier function, and hyperkeratosis of follicular epithelium in patients with acne. However, these hypotheses should be confirmed by further histopathologic analysis via biopsies of post-treatment lesions.

Present acne treatments have several shortcomings. Topical agents are often irritating. Response to oral antibiotics is generally slow, and continuous treatment for several months is usually required. Additionally, long-term use of antibiotics may cause an increase in antibiotic-resistant strains of *P. acnes*, which leads to treatment failure.²⁴ Oral retinoids are highly teratogenic, frequently produce mucocutaneous xerosis, and occasionally lead to depression.^{25,26} Topical rhEGF, on the other hand, is less irritating, quickly improves acne lesions, and effectively reduces sebum output level.

In conclusion, rhEGF is currently not widely utilized in the treatment of acne, and there have been no previous blinded controlled clinical trials in peer-reviewed literature that examine the role of rhEGF in acne vulgaris. This study

demonstrated improvement of inflammatory and non-inflammatory acne lesions based on investigators' lesion counts and acne severity scoring. In addition, this therapy showed minimal adverse effects, which are frequently observed with conventional acne treatments. Topical rhEGF may be a useful adjuvant therapeutic option for acne.

There are some limitations to this study that should be noted. First, our study did not reflect individual hormonal changes, which can influence the results in female patients. Second, this was a small study, and additional studies with larger sample size are needed to confirm our results. However, to the best of our knowledge, this is the first double-blinded, vehicle-controlled study to demonstrate the efficacy of topical rhEGF in acne vulgaris. Further studies will be helpful to clarify the exact role of EGF as a novel addition to current acne treatment strategies.

Acknowledgement

This work was supported by the Infrastructure program for new-growth Industries (10044186, Development of Smart Beauty Devices Technology and Establishment of Commercialization Support Center) funded by the Ministry of Trade, industry & Energy (MI, Korea).

References

- 1 Marchese C, Chedid M, Dirsch OR, *et al.* Modulation of keratinocyte growth factor and its receptor in reepithelializing human skin. *J Exp Med* 1995; **182**: 1369–1376.
- 2 Ishibashi T, Shinogami M, Ishimoto S, *et al.* Induction of KGF, basic FGF, and TGF mRNA expression during healing of experimental TM perforations. *Acta Otolaryngol* 1998; **118**: 701–704.
- 3 Pilcher BK, Gaither-Ganim J, Parks WC, *et al.* Cell type-specific inhibition of keratinocyte collagenase-1 expression by basic fibroblast growth factor and keratinocyte growth factor: a common receptor pathway. *J Biol Chem* 1997; **272**: 18147–18154.
- 4 McCawley LJ, O'Brien P, Hudson LG. Epidermal growth factor (EGF)- and scatter factor/hepatocyte growth factor (SF/HGF)-mediated keratinocyte migration is coincident with induction of matrix metalloproteinase (MMP)-9. *J Cell Physiol* 1998; **176**: 255–265.
- 5 Cohen S. Isolation of mouse submaxillary gland protein accelerating incisor eruption and eyelid opening in the new born animal. *J Biol Chem* 1962; **237**: 1555–1562.
- 6 Nanney LB. Epidermal and dermal effect of epidermal growth factor during wound repair. *J Invest Dermatol* 1990; **94**: 624–629.
- 7 Servold SA. Growth factor impact on wound healing. *Clin Podiatr Med Surg* 1991; **8**: 937–953.

- 8 Brown GL, Curtsinger L, Brightwell JR, *et al.* Enhancement of epidermal regeneration by biosynthetic epidermal growth factor. *J Exp Med* 1986; 163: 1319–1324.
- 9 Baselag J. Why the epidermal growth factor receptor? The rationale for cancer therapy *Oncologist* 2002; 7: 2–8.
- 10 Arteaga CL. The epidermal growth factor receptor: from mutant oncogene in nonhuman cancers to therapeutic target in human neoplasia. *J Clin Oncol* 2001; 19: 325–40S.
- 11 Hu JC, Sadeghi P, Pinter-Brown LC, *et al.* Cutaneous side-effects of epidermal growth factor receptor inhibitors: clinical presentation, pathogenesis, and management. *J Am Acad Dermatol* 2007; 56: 317–326.
- 12 Akimoto N, Sato T, Sakiguchi T, *et al.* Cell proliferation and lipid formation in hamster sebaceous gland cells. *Dermatology* 2002; 204: 118–123.
- 13 Sato T, Imai N, Akimoto N, *et al.* Epidermal growth factor and 1 α ,25-dihydroxyvitamin D₃ suppress lipogenesis in hamster sebaceous gland cells in vitro. *J Invest Dermatol* 2001; 117: 965–970.
- 14 Shin JU, Park JH, Cho BC, *et al.* Treatment of epidermal growth factor receptor inhibitor-induced acneiform eruption with topical recombinant human epidermal growth factor. *Dermatology* 2012; 225: 135–140.
- 15 Rivera AE. Acne scarring: a review and current treatment modalities. *J Am Acad Dermatol* 2008; 59: 659–676.
- 16 Wollenberg A, Kroth J, Hauschild A, *et al.* Cutaneous side effects of EGFR inhibitors – appearance and management. *Dtsch Med Wochenschr* 2010; 135: 149–154.
- 17 Busam KJ, Capodici P, Motzer R, *et al.* Cutaneous side-effects in cancer patients treated with the anti-epidermal growth factor receptor antibody C225. *Br J Dermatol* 2001; 144: 1169–1176.
- 18 Nikolaou V, Strimpakos AS, Stratigos A, *et al.* Azithromycin pulses for the treatment of epidermal growth factor receptor inhibitor-related papulopustular eruption: an effective and convenient alternative to tetracyclines. *Dermatology* 2012; 224: 315–319.
- 19 Green MR, Basketter DA, Couchman JR, *et al.* Distribution and number of epidermal growth factor receptors in skin is related to epithelial cell growth. *Dev Biol* 1983; 100: 506–512.
- 20 Matias JR, Orentreich N. Stimulation of hamster sebaceous glands by epidermal growth factor. *J Invest Dermatol* 1983; 80: 516–519.
- 21 Casacó A, Ledón N, González A, *et al.* Topical anti-inflammatory activity of human recombinant epidermal growth factor. *Skin Pharmacol Appl Skin Physiol* 1999; 12: 79–84.
- 22 Pastore S, Mascia F, Mariotti F, *et al.* ERK1/2 regulates epidermal chemokine expression and skin inflammation. *J Immunol* 2005; 174: 5047–5056.
- 23 Pérez-Soler R. Can rash associated with HER1/EGFR inhibition be used as a marker of treatment outcome? *Oncology* 2003; 17: 23–28.
- 24 Dreno B. Topical antibacterial therapy for acne vulgaris. *Drugs* 2004; 64: 2389–2399.
- 25 Griffin JP. A review of the literature on benign intracranial hypertension associated with medication. *Adverse Drug React Toxicol Rev* 1992; 11: 41–57.
- 26 Stern RS. When a uniquely effective drug is teratogenic. The case of isotretinoin. *N Engl J Med* 1989; 320: 1007–1009.