

# UC Davis

## Dermatology Online Journal

### Title

Ashy dermatosis: a review

### Permalink

<https://escholarship.org/uc/item/44f462s8>

### Journal

Dermatology Online Journal, 25(5)

### Authors

Nguyen, Khoa  
Khachemoune, Amor

### Publication Date

2019

### License

[CC BY-NC-ND 4.0](#)

Peer reviewed

# Ashy dermatosis: a review

Khoa Nguyen<sup>1</sup> BS, Amor Khachemoune<sup>2,3</sup> MD FAAD FACMS

Affiliations: <sup>1</sup>University of Central Florida College of Medicine, Orlando, Florida, USA, <sup>2</sup>Veterans Affairs Medical Center, Brooklyn, New York, USA, <sup>3</sup>SUNY Downstate, Department of Dermatology, Brooklyn, New York, USA

Corresponding Author: Amor Khachemoune MD, FAAD, FACMS, 800 Poly Place, Dermatology Service, Brooklyn, NY, 11209, Tel: 718-270-1000, Email: [amorkh@gmail.com](mailto:amorkh@gmail.com)

## Abstract

Ashy dermatosis is characterized by asymptomatic, symmetrically-distributed, gray-colored macules located on the trunk, neck, face, and upper extremities. The condition occurs most commonly in patients with Fitzpatrick phototype III-V skin. The etiology is unknown, but drug ingestion, infection, and genetic factors have been suggested to elicit ashy dermatosis. No gold standard treatments have been established yet. The most successful treatment to date has been clofazimine, although topical tacrolimus, oral dapsone, narrowband ultraviolet light B phototherapy, and isotretinoin have shown treatment success. Ashy dermatosis is primarily a cosmetic concern, but can be a very distressing condition, especially for dark skinned individuals. Therefore, an increase in clinician awareness and more studies are needed to further understand the etiology and treatment options for this disease. This review serves as a single source for clinicians to stay up-to-date regarding the history, clinical presentation, histology, pathogenesis, differential diagnosis, and management options for ashy dermatosis. It also suggests an alternative name that more appropriately encompasses the clinical and histopathologic features, while acknowledging our lack of understanding of its etiology: macular hyperpigmentation of indeterminate etiology.

*Keywords: ashy dermatosis, erythema dyschromicum perstans, lichen planus pigmentosus, macular hyperpigmentation of indeterminate etiology*

## Introduction

Ashy dermatosis is a type of acquired macular hyperpigmentation characterized by asymptomatic, symmetrically-distributed, gray macules of unknown

pathophysiology [1]. Although most commonly found in the Central and South American population, ashy dermatosis demonstrates a worldwide prevalence [2-5]. Ashy dermatosis can appear at any season of the year in patients of any age group or gender [2, 6]. Although primarily a cosmetic issue, its prevalence and prominent appearance in dark skinned individuals can be very troubling for patients. Therefore, this rare, dermatologic condition warrants increased clinician awareness.

Ashy dermatosis has been commonly referred to as erythema dyschromicum perstans and some authors feel that it is synonymous with lichen planus pigmentosus. Unfortunately, the plethora of names from different countries for this presentation makes it difficult to make meaningful advances in our understanding of this disease. This ashy dermatosis review serves as a single source for clinicians to stay up-to-date regarding the history, clinical presentation, histologic features, pathogenesis, differential diagnosis, management, and outcomes. A literature search was performed using MEDLINE (Ovid SP and PubMed). Search terms used in this database were as follows: "ashy dermatosis," "erythema dyschromicum perstans," OR "lichen planus pigmentosus." The search date range was selected from January 1, 1970 through December 31, 2018.

## History

Ashy dermatosis was first described in 1957 by Ramirez in El Salvador as "Los Cenicientos," or the ashen ones, for its asymptomatic, ash-colored, macular hyperpigmentation [7]. This clinical presentation was later described in 1961 as erythema dyschromicum perstans by Convit in Caracas [8]. The relationship between ashy

dermatosis and erythema dyschromicum perstans is still debated, with many considering the two to be identical in the literature. Most recently, Zaynoun proposed the classification of erythema dyschromicum perstans to display lesion characteristics similar to ashy dermatosis, but that erythema dyschromicum perstans also includes lesions that currently present with or have had erythematous borders [9]. Other labels that may have been used or confused with ashy dermatosis in the past include Riehl's melanosis, Cinderella dermatosis, erythema chronicum figuratum melanodermicum, and lichen planus pigmentosus [10, 11].

### Clinical Presentation

Ashy dermatosis presents as slowly progressive, gray-colored, macular hyperpigmentation that is deeper than epidermal pigmentary disorders (**Figure 1**). It occurs most often in patients with Fitzpatrick skin type III-V phototypes [4]. Lesions can be symmetrically distributed over the trunk, neck, upper extremities, and face [4, 12]. Ashy dermatosis lesions typically start as small, 3mm size macules but can slowly coalesce to form large patches over the course of several weeks (**Figure 2**). Lesions typically spare the palms, soles, nails, and mucous membranes. However, reports exist of lesions occurring in the oral mucosa [13]. It is typically asymptomatic. Atypical lesions can be accompanied by peripheral erythematous borders, pruritus, or

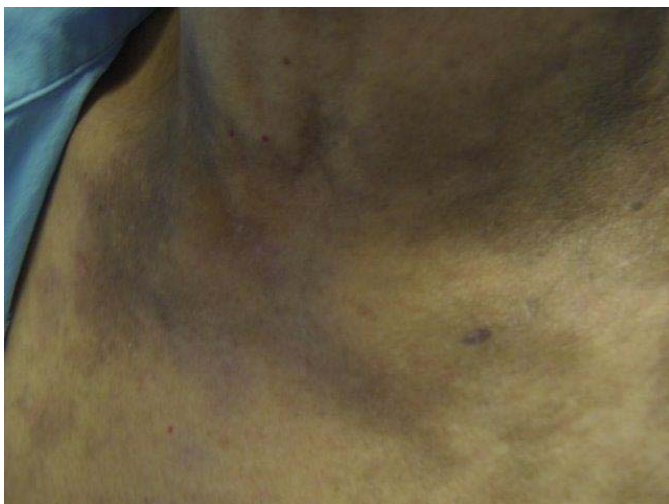scaling [4, 14]. The lesions can become confluent and involve almost the whole skin, with no preference for photoexposed areas [15].

Dermoscopy can assist in differentiating ashy dermatosis from other similar dermatoses by displaying gray-bluish small dots over a bluish background, corresponding to melanophages or melanin deposits in the deeper dermis [16].

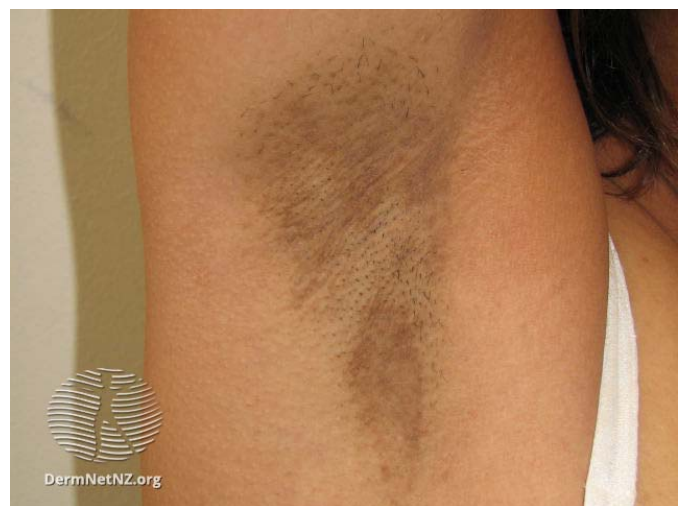### Histology

Characteristic histology features, although not pathognomonic, depend on the lesion phase. Active or early lesions can display basal vacuolar degeneration, papillary dermis edema, or perivascular lymphocytic infiltration [4]. Inactive or late lesions demonstrate pigment incontinence in the dermis and melanophages (**Figure 3**). As lesions progress, inflammatory infiltrate diminishes. Perivascular or subepidermal fibrosis, pigmentary alteration, or lichenoid infiltration can also be seen [17, 18]. The lichenoid changes could be restricted to the periphery of the lesion and can be missed if not included in the biopsy [2].

Direct immunofluorescence showing colloid IgM suggests a diagnosis of ashy dermatosis [18]. The presence of cutaneous lymphocyte antigen positive cells in the basement membrane zone suggests that ashy dermatosis can be a response to antigenic stimulation [19]. There is excess expression of intercellular adhesion molecule 1 and HLA-DR in the



**Figure 1.** Symmetric hyperpigmented oval brown patches on the neck and upper trunk of a 51-year-old Hispanic female.



**Figure 2.** Hyperpigmented macules that have coalesced into a large patch in the axilla of a patient. Reprinted with permission from [www.dermnetnz.org](http://www.dermnetnz.org).

keratinocyte basal cell layer of ashy dermatosis lesions [20]. Further, individuals with ashy dermatosis have an abnormal expression of CD36 (thrombospondin receptor) not expressed by normal skin, in the strata spinosum and granulosum [20].

### Etiology/Pathogenesis

The etiology of ashy dermatosis is unknown. There are no lab tests or radiographic studies that are pathognomonic. Many predisposing factors have been cited including: infections such as intestinal parasitism (control of which produced remission of active skin lesions), [21], enterovirus [22], HIV seroconversion [23], and chronic hepatitis C [24]; environmental insults such as ingestion of ammonium nitrate [25], orally administered X-ray contrast media [26], ethambutol [27], fluoxetine [28],

chlorothalonil [29], and omeprazole [30]; and genetic factors such as the HLA-DR4 allele [12]. Similar macules have been described in individuals with a cobalt allergy [31].

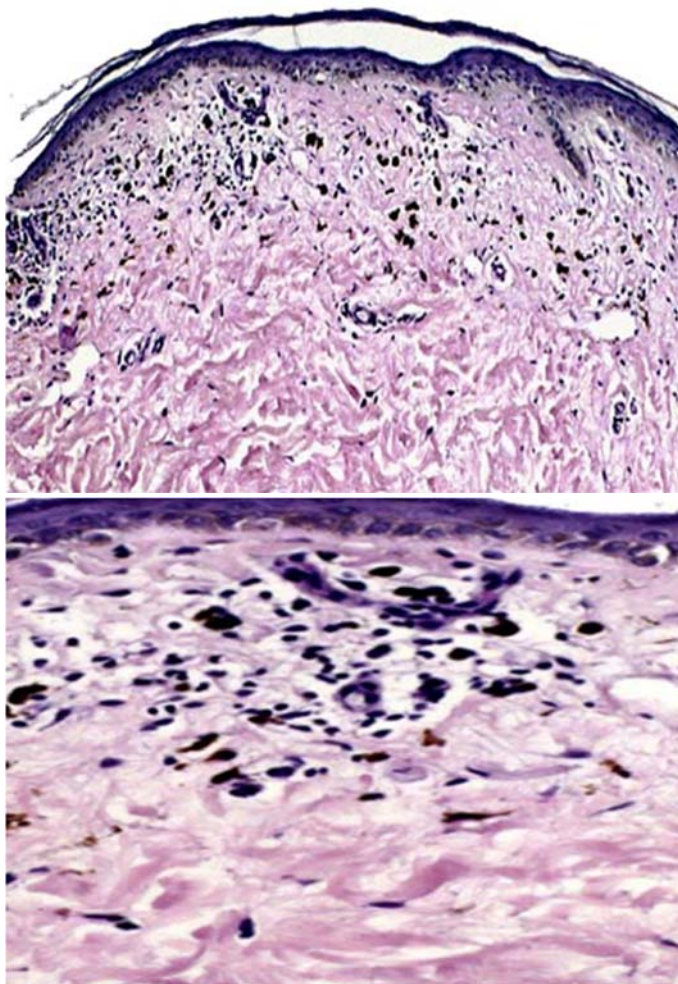
### Differential Diagnosis

Controversy exists whether ashy dermatosis and lichen planus pigmentosus are separate clinical diagnoses. There are some clinical differences between ashy dermatosis and lichen planus pigmentosus such as the presence of pruritus and burning sensation. Lichen planus pigmentosus has a more localized distribution with facial involvement, compared with the typical truncal involvement in ashy dermatosis [32]. Palmoplantar involvement can be found in both conditions [33]. In addition, lichen planus pigmentosus exhibits a waxing and waning course as compared to the stable clinical course seen in ashy dermatosis [32].

Dermoscopic examination of lichen planus pigmentosus can reveal a diffuse brown background with pseudo-networks and gray globules and blotches [34]. In vivo reflectance confocal microscopy consistently shows blurring of the papillary dermis with dense and highly refractive lymphocytes in the superficial dermis [35]. Histologically, ashy dermatosis lacks a well-defined histopathological profile. Furthermore, its tendency to exhibit a lichenoid reaction can be very similar to other inflammatory disorders. Because ashy dermatosis and lichen planus pigmentosus both display similar histologic features, differentiating between the two is challenging [36].

Macules can present along the lines of Blaschko and mimic pityriasis rosea [37]. Ashy dermatosis macules typically persist as compared to the spontaneous resolution seen in pityriasis rosea. However, in individuals with a history of pityriasis rosea, it is reasonable to conclude that the gray macules can be classified as a postinflammatory hyperpigmentation related to pityriasis rosea.

Idiopathic eruptive macular pigmentation may resemble ashy dermatosis owing to the clinical features of asymptomatic, nonconfluent brown macules located on the trunk, neck, and proximal extremities. Histopathologic findings can include



**Figure 3.** Low (top, H&E, 20×) and high (bottom, H&E, 100×) power histologic images showing epidermal atrophy, focal vacuolar alteration of basal cells, perivascular lymphoid cell infiltrate, and numerous melanophages.

hyperpigmentation of the epidermal basal layer, prominent dermal melanophages, or lichenoid inflammatory infiltrate with normal mast cell counts [38]. Spontaneous resolution is expected within several months or years, which is similar to ashy dermatosis in children, but differs from ashy dermatosis in adults. However, the pigmented macules in idiopathic eruptive macular hyperpigmentation are smaller in size (ranging from 5 to 25mm) as compared to the larger macules (3mm or larger) and patches seen in ashy dermatosis [39].

Post-inflammatory hyperpigmentation differs in the history, clinical presentation, dermoscopy features, and histology findings. A fixed drug eruption may appear similar to ashy dermatosis, but differs in that a fixed drug eruption is more circular in shape and brown in color as compared to the gray color in ashy dermatosis.

### Management and Outcomes

It is important to obtain a thorough medical history with an emphasis on medication or drug ingestion. Physical examination should include an oral and genital examination. Punch biopsy may be indicated to exclude other causes of hyperpigmentation, particularly lichen planus.

The clinical course of ashy dermatosis is different between children and adults. In children, ashy dermatosis typically resolves in two to three years [2, 40]. Although spontaneous resolution in adults has been reported, ashy dermatosis lesions in adults usually persist and have a chronic course [41].

No gold standard exists for treatment of ashy dermatosis. Chang et al. [4] administered a variety of topical (steroids, hydroquinone, calcineurin inhibitors, and tretinoin) and systemic treatments (dapson, minocycline, tranexamic acid, clofazimine, pentoxifylline, and macrolides). However, most cases (55%) did not respond or worsened.

Treatment with clofazimine is the most commonly used medication despite its lack of curative effect [3]. One clinical trial achieved an excellent to good response in seven of eight patients treated with clofazimine. Histologic analysis revealed that, after clofazimine therapy, expression of intercellular adhesion molecule 1, HLA-DR, and mononuclear cell

infiltrate disappeared [20]. In addition, clofazimine masks the lesions by causing a homogeneous coloration of the skin, rendering a cosmetic effect. Other potential therapeutic options, albeit with variable efficacy and recurrence rates, include topical tacrolimus 0.1% [42], oral dapsone [43], isotretinoin [44], and narrowband ultraviolet light B phototherapy [45].

Light therapy is a promising treatment modality. Although non-ablative fractional laser treatment alone was ineffective in treating ashy dermatosis, one recent report highlighted >75% improvement with maintenance after eight months after treatment with non-ablative fractional laser in combination with topical tacrolimus 0.1% ointment [46]. However, laser-induced postinflammatory hyperpigmentation can occur, further exacerbating the cosmetic concerns in ashy dermatosis [47].

Ashy dermatosis can often be misdiagnosed or confused with lichen planus pigmentosus given their overlapping features. However, successfully reported treatments are largely the same. Topical tacrolimus for 8 weeks renders moderate treatment success in lichen planus pigmentosus [48]. Q-switched Nd-YAG laser in combination with topical tacrolimus is also effective in treating stable lichen planus pigmentosus [49].

### Time for a Name Reappraisal

The name ashy dermatosis has been upheld since it was conceived in 1957 by Ramirez in El Salvador. Although the name is partially descriptive of its appearance, there does not appear to be enough evidence to distinguish it from lichen planus pigmentosus or erythema dyschromicum perstans. The main differentiating points between the aforementioned diagnoses are too imperceptible (erythematous ring surrounding a macule) or too variable (pruritus, symmetry, histopathology).

Traditionally, the erythematous halo surrounding a macule has been the differentiating factor that suggests a diagnosis of ashy dermatosis over lichen planus pigmentosus. However, in one clinicopathologic study involving 31 cases of ashy dermatosis and lichen planus pigmentosus, this critical feature was present in only 40% of ashy dermatosis diagnoses [36]. Furthermore, there were

insignificant differences in the histologic features between the two. Chandran et al. [1] recently proposed that patients with the clinical features of lichen planus concurrent with the gray macules should be classified as having lichen planus pigmentosus. Though helpful if present, only 9% of patients presenting with the lichen planus pigmentosus also observed lichen planus, limiting its utility in classifying lichen planus pigmentosus over ashy dermatosis [36].

It is difficult to advance our understanding of this disease when clinicians from different countries have different names for this presentation. For now, we propose the nomenclature “macular hyperpigmentation of indeterminate etiology.” We believe that this name properly incorporates the clinical and histopathologic characteristics, while acknowledging our lack of understanding of the pathogenesis.

## References

- Chandran V, Kumarasinghe SP. Macular pigmentation of uncertain aetiology revisited: two case reports and a proposed algorithm for clinical classification. *Aust J Dermatol*. 2017;58(1):45-9. [PMID: 26831572].
- Torrelo A, Zaballos P, Colmenero I, Mediero IG, De Prada I, Zambrano A. Erythema dyschromicum perstans in children: a report of 14 cases. *J Eur Acad Dermatol Venereol*. 2005;19(4):422-6. [PMID: 15987286].
- Schwartz RA. Erythema dyschromicum perstans: the continuing enigma of Cinderella or ashy dermatosis. *Int J Dermatol*. 2004;43(3):230-2. [PMID: 15009400].
- Chang SE, Kim HW, Shin JM, Lee JH, Na JI, Roh MR, Lee JH, Lee GY, Ko JY. Clinical and histological aspect of erythema dyschromicum perstans in Korea: A review of 68 cases. *J Dermatol*. 2015;42(11):1053-7. [PMID: 26118942].
- Keisham C, Sarkar R, Garg VK, Chugh S. Ashy dermatosis in an 8-year-old Indian child. *Indian Dermatol Online J*. 2013;4(1):30-2. [PMID: 23439983].
- Harvell JD, Selig DJ. Seasonal variations in dermatologic and dermatopathologic diagnoses: a retrospective 15-year analysis of dermatopathologic data. *Int J Dermatol*. 2016;55(10):1115-8. [PMID: 27061329].
- Ramirez C. Proceedings of the first Central American Congress of Dermatology; San Salvador. Dec, 5 - Aug. 1957. *Los Cenicientos: problema Clinico*. 1957:122-30.
- Convit J, Kerdel-Vegas F, Rodríguez G. Erythema Dyschromicum Perstans: A Hitherto Undescribed Skin Disease\*. *J Invest Dermatol*. 1961;36(6):457-62. [DOI: 10.1038/jid.1961.70].
- Zaynoun S, Rubeiz N, Kibbi A-G. Ashy dermatoses – a critical review of the literature and a proposed simplified clinical classification. *Int J Dermatol*. 2008;47(6):542-4. [PMID: 18477140].
- Kaminsky A. Erythema figuratum. *Actas Dermosifiliogr*. 2009;100 Suppl 2:88-109. [PMID: 20096167].
- Kumarasinghe SPW, Pandya A, Chandran V, Rodrigues M, Dlova NC, Kang HY, Ramam M, Dayrit JF, Goh BK, Parsad D. A global consensus statement on ashy dermatosis, erythema dyschromicum perstans, lichen planus pigmentosus, idiopathic eruptive macular pigmentation, and Riehl's melanosis. *Int J Dermatol*. 2018. [PMID: 30176055].
- Correa MC, Memije EV, Vargas-Alarcon G, Guzman RA, Rosetti F, Acuna-Alonzo V, Martinez-Rodriguez N, Granados J. HLA-DR association with the genetic susceptibility to develop ashy dermatosis in Mexican Mestizo patients. *J Am Acad Dermatol*. 2007;56(4):617-20. [PMID: 17116345].
- Rato M, Monteiro AF, Aranha J, Tavares E. Ashy dermatosis with involvement of mucous membranes. *An Bras Dermatol*. 2017;92(5 Suppl 1):17-20. [PMID: 29267435].
- Ono S, Miyachi Y, Kabashima K. Ashy dermatosis with prior pruritic and scaling skin lesions. *J Dermatol*. 2012;39(12):1103-4. [PMID: 22458632].
- Tlougan BE, Gonzalez ME, Mandal RV, Kundu RV, Skopicki D. Erythema dyschromicum perstans. *Dermatol Online J*. 2010;16(11):17. [PMID: 21163168].
- Errichetti E, Angione V, Stinco G. Dermoscopy in assisting the recognition of ashy dermatosis. *JAAD Case Rep*. 2017;3(6):482-4. [PMID: 28975145].
- Martin JM, Lopez V, Jorda E, Monteagudo C. Ashy dermatosis with significant perivascular and subepidermal fibrosis. *Am J Dermatopathol*. 2008;30(5):510-2. [PMID: 18806503].
- Tienthavorn T, Tresukosol P, Sudtikoonaseth P. Patch testing and histopathology in Thai patients with hyperpigmentation due to Erythema dyschromicum perstans, Lichen planus pigmentosus, and pigmented contact dermatitis. *Asian Pac J Allergy Immunol*. 2014;32(2):185-92. [PMID: 25003734].
- Vasquez-Ochoa LA, Isaza-Guzman DM, Orozco-Mora B, Restrepo-Molina R, Trujillo-Perez J, Tapia FJ. Immunopathologic study of

## Conclusion

Ashy dermatosis is characterized by asymptomatic, symmetrically-distributed, gray-colored macules located on the trunk, neck, face, and upper extremities. Although primarily a cosmetic concern, ashy dermatosis can be a very distressing dermatologic condition, especially in patients with Fitzpatrick phototype III-V skin. Therefore, an increase in clinician awareness and additional studies are needed to further understand the pathogenesis and successful treatment options for this disease. We propose that “macular hyperpigmentation of indeterminate etiology” replace ashy dermatosis as it a more accurate and more appropriate name for this condition.

## Potential conflicts of interest

The authors declare no conflicts of interests.

- erythema dyschromicum perstans (ashy dermatosis). *Int J Dermatol*. 2006;45(8):937-41. [PMID: 16911378].
20. Baranda L, Torres-Alvarez B, Cortes-Franco R, Moncada B, Portales-Perez DP, Gonzalez-Amaro R. Involvement of cell adhesion and activation molecules in the pathogenesis of erythema dyschromicum perstans (ashy dermatitis). The effect of clofazimine therapy. *Arch Dermatol*. 1997;133(3):325-9. [PMID: 9080892].
  21. Stevenson JR, Miura M. Erythema dyschromicum perstans (ashy dermatosis). *Arch Dermatol*. 1966;94(2):196-9. [PMID: 5911505].
  22. Melo CR, Sa MC, Carvalho S. Erythema dyschromicum perstans in a child following an enteroviral meningitis. *An Bras Dermatol*. 2017;92(1):137-8. [PMID: 28225976].
  23. Venencie PY, Foldes C, Laurian Y, Lemarchand-Venencie F, Lemay D, Verroust F. Erythema dyschromicum perstans following human immunodeficiency virus seroconversion in a child with hemophilia B. *Arch Dermatol*. 1988;124(7):1013-4. [PMID: 3389844].
  24. Kontochristopoulos GJ, Aroni K, Anagnostopoulos G, Nakopoulou L, Tassopoulos NC. Erythema dyschromicum perstans and hepatitis C virus infection. *Int J Dermatol*. 2001;40(5):346-8. [PMID: 11555000].
  25. Jablonska S. Ingestion of ammonium nitrate as a possible cause of erythema dyschromicum perstans (ashy dermatosis). *Dermatologica*. 1975;150(5):287-91. [PMID: 1183692].
  26. Lambert WC, Schwartz RA, Hamilton GB. Erythema dyschromicum perstans. *Cutis*. 1986;37(1):42-4. [PMID: 3948533].
  27. Srivastava N, Solanki LS, Chand S, Garbyal RS, Singh S. Ashy dermatosis-like pigmentation due to ethambutol. *Indian J Dermatol Venereol Leprol*. 2008;74(3):281-2. [PMID: 18583814].
  28. Bernardes F. Fluoxetine/paroxetine Ashy dermatosis: case report. *Reactions*. 2012;1401:12. [DOI: 10.2165/00128415-201214010-00063].
  29. Penagos H, Jimenez V, Fallas V, O'Malley M, Maibach HI. Chlorothalonil, a possible cause of erythema dyschromicum perstans (ashy dermatitis). *Contact dermatitis*. 1996;35(4):214-8. [PMID: 8957640].
  30. Chua S, Chan MMF, Lee HY. Ashy dermatosis (erythema dyschromicum perstans) induced by omeprazole: a report of three cases. *Int J Dermatol*. 2015;54(10):e435-e6. [PMID: 26146873].
  31. Zenorola P, Bisceglia M, Lomuto M. Ashy dermatosis associated with cobalt allergy. *Contact dermatitis*. 1994;31(1):53-4. [PMID: 7924301].
  32. Cheng HM, Chuah SY, Gan EY, Jhingan A, Thng STG. A retrospective clinico-pathological study comparing lichen planus pigmentosus with ashy dermatosis. *Aust J Dermatol*. 2018;59(4):322-7. [PMID: 29635779].
  33. Dabas G, Vinay K, Parsad D, Chatterjee D, Kumaran MS. A retrospective study of lichen planus pigmentosus with focus on palmoplantar involvement. *Clin Exp Dermatol*. 2019;44(2):190-3. [PMID: 29947025].
  34. Feng H, Gutierrez D, Rothman L, Meehan S, Sicco KL. Lichen planus pigmentosus. *Dermatol Online J*. 2018;24(12). [PMID: 30677796].
  35. Dai H, Jiang HY, Xu AE. Detection of lichen planus pigmentosus with dermoscopy and reflectance confocal microscopy. *Skin Res Technol*. 2018;24(4):699-700. [PMID: 29790598].
  36. Vega ME, Waxtein L, Arenas R, Hojyo T, Dominguez-Soto L. Ashy dermatosis and lichen planus pigmentosus: a clinicopathologic study of 31 cases. *Int J Dermatol*. 1992;31(2):90-4. [PMID: 1559749].
  37. Yokozeki H, Ueno M, Komori K, Nishioka K. Multiple linear erythema dyschromicum perstans (ashy dermatosis) in the lines of Blaschko. *Dermatology (Basel, Switzerland)*. 2005;210(4):356-7. [PMID: 15942229].
  38. Sanz de Galdeano C, Leaute-Labreze C, Bioulac-Sage P, Nikolic M, Taieb A. Idiopathic eruptive macular pigmentation: report of five patients. *Pediatr Dermatol*. 1996;13(4):274-7. [PMID: 8844742].
  39. Stinco G, Favot F, Scott CA, Patrone P. Pigmentatio maculosa eruptiva idiopathica: a case report and review of the literature. *Int J Dermatol*. 2007;46(12):1267-70. [PMID: 18173521].
  40. Silverberg NB, Herz J, Wagner A, Paller AS. Erythema dyschromicum perstans in prepubertal children. *Pediatr Dermatol*. 2003;20(5):398-403. [PMID: 14521555].
  41. Antonov NK, Braverman I, Subtil A, Halasz CL. Erythema dyschromicum perstans showing resolution in an adult. *JAAD Case Rep*. 2015;1(4):185-7. [PMID: 27051725].
  42. Mahajan VK, Chauhan PS, Mehta KS, Sharma AL. Erythema Dyschromicum Perstans: Response to Topical Tacrolimus. *Indian J Dermatol*. 2015;60(5):525. [PMID: 26538750].
  43. Bahadir S, Çobanoğlu Ü, Çimsit G, Yaylı S, Alpay K. Erythema dyschromicum perstans: Response to dapsone therapy. *Int J Dermatol*. 2004;43(3):220-2. [PMID: 15009398].
  44. Wang F, Zhao YK, Wang Z, Liu JH, Luo DQ. Erythema Dyschromicum Perstans Response to Isotretinoin. *JAMA Dermatol*. 2016;152(7):841-2. [PMID: 26933923].
  45. Fabbrocini G, Cacciapuoti S, Izzo R, Mascolo M, Staibano S, Monfrecola G. Efficacy of narrowband UVB phototherapy in erythema dyschromicum perstans treatment: case reports. *Acta Dermatovenerol Croat: ADC*. 2015;23(1):63-5. [PMID: 25969916].
  46. Wolfshohl JA, Geddes ER, Stout AB, Friedman PM. Improvement of erythema dyschromicum perstans using a combination of the 1, 550-nm erbium-doped fractionated laser and topical tacrolimus ointment. *Lasers Surg Med*. 2017;49(1):60-2. [PMID: 27552666].
  47. Kroon MW, Wind BS, Meesters AA, Wolkerstorfer A, van der Veen JP, Bos JD, Van der Wal AC, Beek JF. Non-ablative 1550 nm fractional laser therapy not effective for erythema dyschromicum perstans and postinflammatory hyperpigmentation: a pilot study. *J Dermatol Treat*. 2012;23(5):339-44. [PMID: 21756152].
  48. Wu A, Vaidya S. Literature Review of Treatment Outcomes for Lichen Planus Pigmentosus, Erythema Dyschromicum Perstans, and Ashy Dermatitis. *J Cutan Med Surg*. 2018;22(6):643-5. [PMID: 30322299].
  49. Shah DSD, Aurangabadkar DS, Nikam DB. An open-label non-randomized prospective pilot study of the efficacy of Q-switched Nd-YAG laser in management of facial lichen planus pigmentosus. *J Cosmet Laser Ther*. 2019;21(2):108-15. [PMID: 29768073].