




ACTAS Derma-Sifiliográficas

Full English text available at
www.actasdermo.org



NOVELTIES IN DERMATOLOGY

New Treatments for Hair Loss[☆]



S. Vañó-Galván,^{a,*} F. Camacho^b

^a Servicio de Dermatología, Unidad de Tricología, Hospital Universitario Ramón y Cajal, IRYCIS, Universidad de Alcalá, Madrid, Spain

^b Hospital Virgen Macarena, Sevilla, Spain

Received 18 September 2016; accepted 6 November 2016

Available online 3 March 2017

KEYWORDS

Hair loss treatments;
Androgenetic alopecia;
Dutasteride;
Alopecia areata;
Ruxolitinib;
Frontal fibrosing alopecia;
Wnt pathway;
Low-level laser therapy

PALABRAS CLAVE

Tricología;
Alopecia androgénica;
Dutasterida;
Alopecia areata;
Ruxolitinib;
Alopecia frontal fibrosante;
Vía Wnt;
Láser de baja potencia

Abstract The treatment of hair loss is an important part of clinical dermatology given the prevalence of the problem and great impact on patients' quality of life. Many new treatments have been introduced in recent years. This review summarizes the main ones in 4 groups: a) For androgenetic alopecia, we discuss new excipients for oral minoxidil, dutasteride, and finasteride as well as new forms of application; prostaglandin agonists and antagonists; low-level laser therapy; and regenerative medicine with Wnt signaling activators and stem cell therapy. b) For alopecia areata, Janus kinase inhibitors are reviewed. c) For frontal fibrosing alopecia, we discuss the use of antiandrogens and, for some patients, pioglitazone. d) Finally, we mention new robotic devices for hair transplant procedures and techniques for optimal follicular unit extraction.

© 2016 Elsevier España, S.L.U. and AEDV. All rights reserved.

Novedades terapéuticas en tricología

Resumen La tricología ocupa un área importante dentro de la práctica asistencial de los dermatólogos por la frecuencia de las diferentes tricosis y por el gran impacto que producen en la calidad de vida de los pacientes. Durante los últimos años hemos comprobado la incorporación de muchas novedades terapéuticas en tricología. El objetivo de la presente revisión es resumir de una forma práctica las principales novedades terapéuticas tricológicas, agrupándolas en 4 apartados: a) alopecia androgénica: nuevos excipientes de minoxidil, dutasterida y finasterida oral y nuevas formas de aplicación de estos antiandrógenos, agonistas y antagonistas de las prostaglandinas, láser de baja potencia y medicina regenerativa —activadores de la vía Wnt y terapia con células madre—; b) alopecia areata: fármacos anti-JAK; c) alopecia frontal fibrosante: antiandrógenos y, en algunos pacientes, pioglitazonas, y d) trasplante capilar:

[☆] Please cite this article as: Vañó-Galván S, Camacho F. Novedades terapéuticas en tricología. Actas Dermosifiliogr. 2017;108:221–228.

* Corresponding author.

E-mail address: drsergiovano@gmail.com (S. Vañó-Galván).

nuevos dispositivos tecnológicos y nuevas técnicas de extracción para optimizar la reserva de unidades foliculares.

© 2016 Elsevier España, S.L.U. y AEDV. Todos los derechos reservados.

Introduction

Trichology is an important field within dermatologic practice. The objective of this review article is to provide a practical synopsis of the main therapeutic novelties in trichology, grouping them into 4 areas: androgenetic alopecia (AGA), alopecia areata (AA), scarring alopecia, and hair transplant.

The study methods consisted of the review of articles included in the *Pubmed* and *Medline* databases and in the *clinicaltrials.gov* clinical trials register between 2013 and 2016, and of the preliminary results of therapies presented at international trichology conferences. The authors of this review also describe their personal experience with the different therapies.

Androgenetic Alopecia

New treatment options have recently been introduced for men and women with AGA. Additionally, novel uses of minoxidil and antiandrogens have also been described.

Minoxidil

A recently published meta-analysis has shown the efficacy of minoxidil versus placebo in the treatment of AGA.¹ The authors state that the use of minoxidil is significantly limited by poor compliance due to cosmetic issues, which may be mitigated by the new minoxidil formulations. A Cochrane review article has been published on interventions for female AGA. That review included 47 studies and 5,290 patients and concluded that the application of topical minoxidil at concentrations between 2% and 5% is effective and safe, and is superior to other treatments such as the antiandrogens and low-level laser therapy (LLLT).² A number of studies looking at the new formulations of minoxidil have shown improved efficacy and better tolerance of foam presentations versus the hydroalcoholic solution in both men³ and women⁴ with AGA, due to the lower concentration of propylene glycol, which enhances its cosmetic acceptability. The possibility of using niosomes to improve the topical absorption of minoxidil is also being investigated.⁵ Another novelty is the development of nanoxidil, an active substance with a similar structure to minoxidil, but with a lower molecular weight; it should therefore present better penetration and absorption, although no robust scientific studies have yet been published to support this. Although anecdotal, papers have been published that suggest low-dose oral minoxidil (0.25 mg/d) may be safe and effective in AGA (Sinclair, personal communication), permanent chemotherapy-induced alopecia,⁶ and in moniletrix.⁷ If these results are confirmed, the use of low doses of oral minoxidil could be a very interesting option in patients with AGA.

Antiandrogens

A number of publications with high levels of evidence support the safety of finasteride and dutasteride in men and women with AGA, because of both the low risk of adverse sexual effects (very similar to placebo),^{8,9} and the in-existent increase in the risk of cancer.^{10,11} Regarding one of the most relevant novelties in AGA in recent years, the authors draw attention to the appearance of the drug dutasteride as a safe and effective option in AGA, both in men and in women.¹²⁻¹⁴ This dual 5 α -reductase inhibitor, with a longer half-life than finasteride, has been shown to be more effective than finasteride in predominantly frontal male AGA without presenting additional adverse effects.¹⁴⁻¹⁷ With respect to new methods of administration of the antiandrogens, the study by Moftah et al.¹⁸ stands out because it demonstrates the usefulness and safety of microinjections of dutasteride in female AGA. Those authors described the treatment of 86 women versus 40 controls, finding a 63% improvement in hair density in the active treatment group versus 17% of the control group ($P < .05$), with no side effects. The local injection of dutasteride into the scalp after nerve block may be a useful therapeutic option in male and female AGA either in monotherapy (Fig. 1) or as a complement to traditional treatment. Our working group has performed a study in 5 men with AGA, observing the efficacy of local injections of dutasteride every 3 months, with no side effects or alterations of hormone levels in the blood (in press – data not published). As an alternative to the oral administration of antiandrogens, several articles describe the inhibitory activity of topical 0.25% finasteride on follicular 5- α -reductase, with lower levels of systemic absorption than oral finasteride.^{19,20} Studies of the clinical efficacy of topical 0.5% finasteride performed by Milani et al. are still to be published (personal communication); those authors have shown an improvement in male AGA at 6 months in 70% of patients treated in monotherapy.

Prostaglandins

Among the prostaglandins (PG), the PGF2 analogs latanoprost and bimatoprost are known to stimulate hair growth by prolonging the anagen phase.^{21,22} However, the concentration of these drugs necessary to improve hairy density in AGA is very high (0.1% latanoprost),²² leading to limitations due to their high cost. Recent research is looking at other drugs that block the PGD2 receptor (GPR44), which has an inhibitory effect on hair growth and which is known to be elevated in the scalp of patients with AGA.²³⁻²⁵ Setipiprant (KITH-105) is a orally administered GPR44 receptor inhibitor that is in the clinical trial phase for asthma, but could have a potential application in AGA.²⁶ A phase II clinical trial is underway to evaluate the use of oral setipiprant in comparison with placebo and with

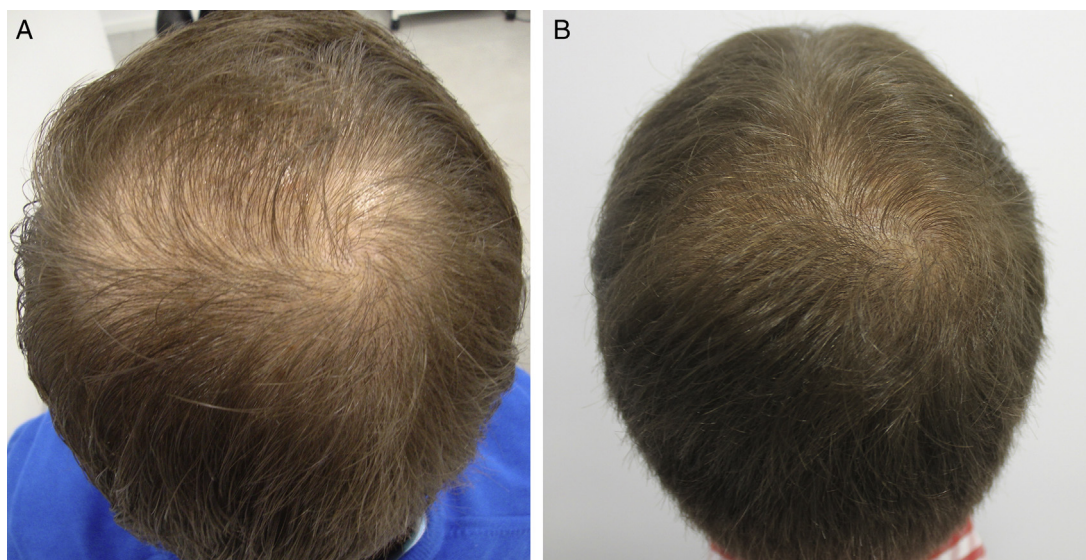


Figure 1 A 26-year-old man with androgenetic alopecia at the vertex. Improvement after treatment with injections of dutasteride in monotherapy every 3 months. A, At baseline. B, After a year of treatment.

finasteride, 1 mg/d, in men aged 18 to 41 years with AGA (NCT02781311).

Physical Therapies

Several methodologically robust articles have demonstrated the usefulness of LLLT in both male and female AGA.²⁷⁻³⁰ The periodic stimulation of hair follicles with LLLT favors the conversion of follicles in telogen to follicles in anagen, and the transformation of vellous follicles into terminal follicles due to the induced perifollicular inflammation, which potentiates follicular growth through activation of stem cells in the bulge. Furthermore, local blood flow is increased and inflammatory mediators and VEGF (vascular endothelial growth factor) are released, favoring the growth of pluripotent stem cells and thus stimulating hair growth and thickening.²⁷⁻³⁰ In the opinion of the authors, the optimal LLLT protocol for men and women with AGA still remains to be defined, although this therapy appears to be an interesting option with a mechanism of action that differs from traditional therapies. Very interesting articles have been published recently on another physical therapy, microneedling,^{31,32} a technique that consists of creating microperforations in the scalp in order to produce controlled damage and the release of endogenous growth factors, which stimulate hair growth.

Regenerative Medicine Therapies

In the final group we have included regenerative medicine therapies designed to stimulate follicular stem cells.

a) Three new studies,³³⁻³⁵ one of which is a meta-analysis,³⁴ have been published on the potential usefulness of platelet-rich plasma (PRP) in male and female AGA, showing PRP to achieve increased hair density and

number of follicles in anagen with virtually no adverse effects. In the opinion of the authors, this treatment has an excellent safety profile, but its efficacy profile is variable, with a very good response in some patients but more modest in others.

- b) The initial results have now been published on the usefulness and safety of topical activators of the Wnt/ β -catenin pathway in AGA: methyl vanillate,³⁶ valproic acid,³⁷ and SM04554.³⁸ The Wnt/ β -catenin pathway regulates activation of the nest of stem cells localized in the follicular bulge, a process necessary for the initiation and maintenance of the follicular anagen phase and whose inhibition has been related with the loss of hair density in AGA.³⁶⁻³⁸
- c) It has recently been reported that pharmacological inhibition of 2 of the signaling pathways implicated in downregulation of the proliferation and differentiation of the follicular bulge stem cells and in initiation of the follicular resting phase, JAK/STAT and mTOR/PI3K, effectively activates hair growth in mouse models and in human follicles in vitro.^{39,40}
- d) It has also been shown that the transient production of reactive oxygen species by photodynamic therapy in vivo in mouse skin induces several signaling pathways that ultimately activate of the nest of hair follicle stem cells, accelerating hair growth.⁴¹
- e) Finally, we would like to comment on stem cell treatments. Basically, there are 2 types of stem cell treatment: E1, which involves hair cloning by the injection of follicular stem cells previously expanded in vitro, producing the growth of new follicles; and E2, adipose-derived stem cells. In the first case, few advances have been reported since the initial studies in mouse models published by McElwee et al. in 2003,⁴² and the preliminary results of the only clinical trial performed in humans were very limited, with an increase in hair growth of only 6% (McElwee, communication at the World Trichology Conference in Barcelona, 2012). Although this treatment

will be a landmark in the treatment of AGA, further research is still required. The second technique consists of performing liposuction to obtain mesenchymal stem cells, which are then conditioned and injected into the scalp to stimulate hair growth. Preliminary studies have shown the possible usefulness of adipose-derived stem cells in AGA,⁴³⁻⁴⁵ but further studies are needed to confirm the safety and efficacy of this therapy.

Alopecia Areata

The therapeutic novelties in the treatment of AA fall into 2 groups: a) new data and forms of application of traditional treatments, and b) new therapies.

- a) In the first group, we draw attention to a review article by Lamb et al.⁴⁶ on the use of immunotherapy with diphencyprone in 133 patients with AA. A response was observed in 72% of patients, with regrowth of over 90% in 16% of cases. Another important novelty in this first group is the use of pulsed systemic corticosteroids in AA. There is evidence of greater safety and at least the same efficacy when corticosteroids are used in pulses.^{47,48} In a study performed by the research group of Hospital Ramón y Cajal in Madrid,⁴⁸ the use of oral dexamethasone at a dose of 0.1 mg/kg/d on 2 consecutive days every week produced regrowth in 25/31 patients with alopecia totalis or universalis (Fig. 2), with mild adverse effects in 32%.
- b) In the second group of novel therapies, the possible usefulness of the combination of simvastatin and ezetimibe in AA stands out for its immunomodulator effect, demonstrated in a study in which 14 of 19 patients with extensive AA responded.⁴⁹ However, other authors have reported significantly lower response rates with this treatment (1/20 patients).⁵⁰ The combination of simvastatin and ezetimibe may be a useful concomitant therapy to improve the response to other treatments, but its action in monotherapy would appear to be limited.

The greatest novelty in the field of AA, and one of the most important in trichology in recent years, is the therapeutic usefulness of the anti-Janus kinase (anti-JAK) agents,⁵¹⁻⁵⁸ not only for their apparent efficacy, but also because these are the first agents that act against a specific pathogenic target in AA. The JAK pathway is implicated in the activation of CD8 cytotoxic T cells and in the production of interferon- γ , which are fundamental to the onset of AA. Their inhibition appears to induce regrowth in these patients. The drugs reported to be potentially useful in AA are tofacitinib⁵⁵⁻⁵⁸ (whose approved indication is rheumatoid arthritis), ruxolitinib^{51,52,54} (approved for use in myelofibrosis and polycythemia vera) and baricitinib⁵³ (pending approval of indication in rheumatoid arthritis). These drugs are administered orally and have an acceptable safety profile; because of their indications, they are usually prescribed for long-term administration and are well tolerated. In addition, the first study has been published on the usefulness of topical ruxolitinib in AA of the eyebrows,⁵² and clinical trials are already underway

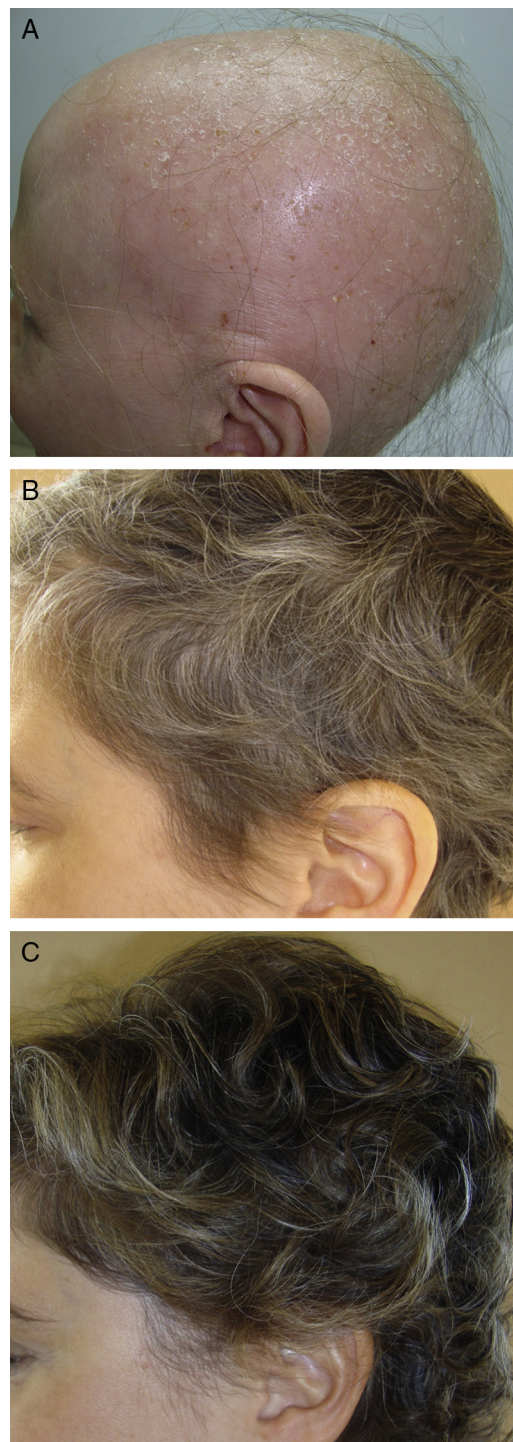


Figure 2 A 34-year-old woman with alopecia areata universalis. Hair regrowth after treatment with oral minipulses of dexamethasone at a dose of 0.1 mg/kg/d on 2 consecutive days each week. A, At baseline. B, Month 4 of treatment. C, Month 8 of treatment.

with new topical anti-JAK agents, such as LEO-124249 (NCT02561585). The main limitation of these treatments is their cost. However, they open new lines of therapeutic research into AA.

Table 1 Summary of the Most Important Therapeutic Novelties in Trichology.

| Area | Novelties in Traditional Treatments | New Therapies |
|--------------------------|---|---|
| • Androgenetic alopecia | <ul style="list-style-type: none"> • Effectiveness of minoxidil in male and female AGA^{1,2} • New foam formulations of minoxidil to improve cosmetic acceptability^{3,4} • Use of niosomes to improve the topical absorption of minoxidil⁵ • Low-dose oral minoxidil • Safety of the 5α-reductase inhibitors⁸⁻¹¹ • Oral dutasteride in male and female AGA¹²⁻¹⁷ | <ul style="list-style-type: none"> • Dutasteride microinjections¹⁸ • Topical finasteride^{19,20} • PGD2-GPR44 inhibitors (setiprant)²⁶ • LLLT²⁷⁻³⁰ • Microneedling^{31,32} • Topical activators of the Wnt/β-catenin pathway³⁶⁻³⁸ • Adipose-derived stem cells⁴³⁻⁴⁵ • Therapy with stem cells previously expanded in vitro⁴² |
| • Alopecia areata | <ul style="list-style-type: none"> • Effectiveness and safety of PRP³³⁻³⁵ • Effectiveness of diphencyprone⁴⁶ • Pulsed corticosteroids^{47,48} | <ul style="list-style-type: none"> • Simvastatin plus ezetimibe^{49,50} • Anti-JAK agents: tofacitinib,⁵⁵⁻⁵⁸ ruxolitinib,^{51,52,54} baricitinib⁵³ |
| • FFA/LPP | <ul style="list-style-type: none"> • Usefulness and safety of the antiandrogens (finasteride and dutasteride) in FFA⁵⁹⁻⁶¹ | <ul style="list-style-type: none"> • Usefulness of pioglitazone in LPP and FFA^{67,71} |
| • Folliculitis decalvans | <ul style="list-style-type: none"> • Effectiveness of treatment with rifampicin plus clindamycin⁷² | <ul style="list-style-type: none"> • Possible usefulness of photodynamic therapy in selected patients⁷³ |
| • Hair transplant | <ul style="list-style-type: none"> • Novel technological devices: robot, automated systems⁷⁵ | <ul style="list-style-type: none"> • New technique of follicular extraction: partial longitudinal extraction⁷⁶ |

Abbreviations: AGA, androgenetic alopecia; FFA, frontal fibrosing alopecia; JAK, Janus kinase; LLLT, low-level laser therapy; LPP, lichen planopilaris; PGD2-GPR44, prostaglandin D2 receptor; PRP, platelet-rich plasma.

Scarring Alopecia

The etiology and pathogenesis of frontal fibrosing alopecia (FFA) are currently considered to involve a double autoimmune and hormonal mechanism.⁵⁹⁻⁶¹ This justifies the use both of anti-inflammatory drugs (corticosteroids) to reduce the autoimmune inflammation and of antiandrogens (finasteride and dutasteride). In recent years, several studies have been published that show the potential usefulness of these drugs in FFA,⁵⁹⁻⁶⁴ including a multicenter Spanish study of 355 patients.⁵⁹ The mechanism by which the antiandrogens act in the FFA is not fully understood, but it would appear that inhibition of the action of male hormones on the root of the follicle helps to stabilize the disease.^{59,61} Some authors have even reported regrowth after the administration of antiandrogens.⁶⁴ However, others remain skeptical regarding the use of these drugs in FFA.⁶⁵ Although their mechanism of action remains unclear, there is evidence that a hormonal factor is responsible for FFA.⁶¹

Another important therapeutic novelty in FFA and lichen planopilaris (LPP) is the use of the oral antidiabetic agent pioglitazone, which blocks the peroxisome proliferator-activated receptor- γ (PPAR γ). Recent studies have suggested that altered function of PPAR- γ may play a role in the initiation of inflammation in LPP and FFA.⁶⁶ Four studies have been published in which pioglitazone has been used to treat LPP and FFA.⁶⁷⁻⁷⁰ Results have been variable, with an efficacy of between 20% and 70% and adverse effects in up to 50%. Marquez and Camacho⁷¹ performed a study in 68 women with FFA, with favorable results in 64% after the use of pioglitazone. The authors believe that pioglitazone could be effective in some cases, but intolerance is not uncommon, mainly in the form of lower limb edema

and weight gain, leading to drug withdrawal in a significant number of cases.

In the case of folliculitis decalvans (FD), a Spanish multicenter study including 82 patients⁷² concluded that the most effective treatment (improvement in 15/15 patients treated) with the longest period of remission after treatment (7.2 months) was the combination of rifampicin plus clindamycin administered for 10 weeks (Fig. 3). Another therapeutic novelty reported in the literature is the possible usefulness of photodynamic therapy (PDT) with benefit in 9 out of 10 patients with FD.⁷³ However, other authors have reported a negative experience with PDT in 3 out of 3 patients.⁷⁴

Hair transplant

To complete this review, 2 novel methods stand out in the field of hair transplant. First, the arrival of the new automated robotic systems that reduce operating times and, in some cases, improve the rates of follicular transection in the follicular unit extraction technique.⁷⁵ However, we consider that results depend more on surgical dexterity than on the device used.

The other novelty is a new technique of follicular extraction, known as partial longitudinal extraction.⁷⁶ This consists of only partially extracting the follicular units, so that the part of the follicle that remains in the donor region can survive and regenerate an intact follicular unit, thus avoiding the progressive depopulation that occurs in the donor region. The concept is interesting, but still needs to be developed.

A summary of the most relevant therapeutic novelties in trichology is presented in Table 1.

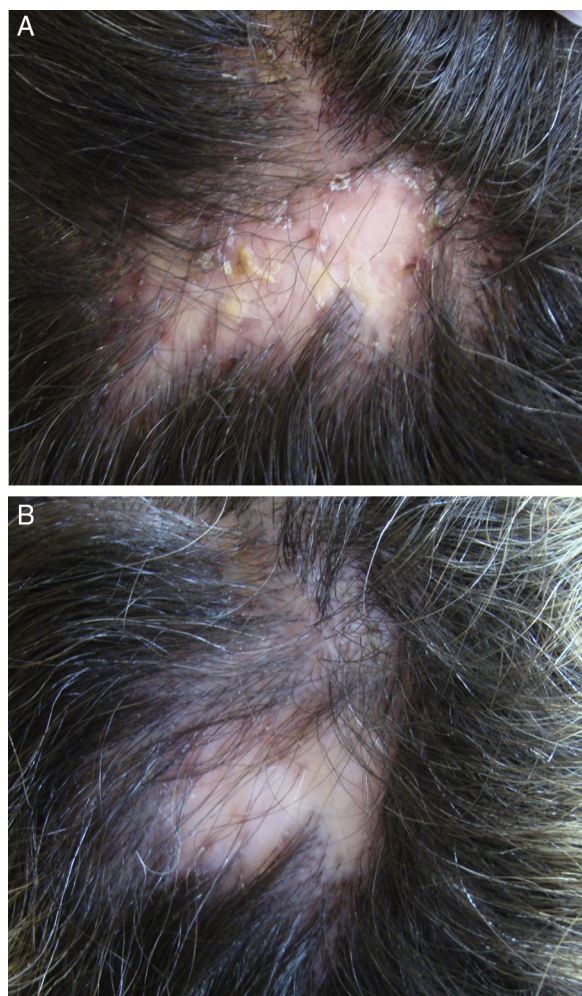


Figure 3 A 33-year-old woman with folliculitis decalvans. Clinical improvement after 10 weeks of treatment with rifampicin, 300 mg every 12 hours, plus clindamycin, 300 mg every 12 hours. A, At baseline. B, At the end of treatment.

Conclusions

In recent years we have seen great advances in the therapeutics of trichology, but more importantly, new lines of research have been opened that will allow us to continue advancing. The developments discussed in this review, which has looked at the past 3 years, are more than hope, they are now a reality.

Conflicts of Interest

The authors declare that they have no conflicts of interest.

References

1. Gupta AK, Charrette A. Topical minoxidil: Systematic review and meta-analysis of its efficacy in androgenetic alopecia. *Skinmed*. 2015;13:185–9 [accessed 16 Ago 2016]. Available at: <http://www.ncbi.nlm.nih.gov/pubmed/26380504>
2. Van Zuuren EJ, Fedorowicz Z, Carter B, Andriolo RB, Schoones J. Interventions for female pattern hair

- loss. *Cochrane Database Syst Rev*. 2012;5:CD007628, <http://dx.doi.org/10.1002/14651858.CD007628.pub3>.
3. Kanti V, Hillmann K, Kottner J, Stroux A, Canfield D, Blume-Peytavi U. Effect of minoxidil topical foam on frontotemporal and vertex androgenetic alopecia in men: A 104-week open-label clinical trial. *J Eur Acad Dermatol Venereol*. 2016;30:1183–9, <http://dx.doi.org/10.1111/jdv.13324>.
4. Blume-Peytavi U, Hillmann K, Dietz E, Canfield D, Garcia Bartels N. A randomized, single-blind trial of 5% minoxidil foam once daily versus 2% minoxidil solution twice daily in the treatment of androgenetic alopecia in women. *J Am Acad Dermatol*. 2011;65:1126–34, <http://dx.doi.org/10.1016/j.jaad.2010.09.724>, e2.
5. Mali N, Darandale S, Vavia P. Niosomes as a vesicular carrier for topical administration of minoxidil: Formulation and in vitro assessment. *Drug Deliv Transl Res*. 2013;3:587–92, <http://dx.doi.org/10.1007/s13346-012-0083-1>.
6. Yang X, Thai KE. Treatment of permanent chemotherapy-induced alopecia with low dose oral minoxidil. *Australas J Dermatol*. 2015, <http://dx.doi.org/10.1111/ajd.12350> [accessed 16 Ago 2016]. Available at: <http://www.ncbi.nlm.nih.gov/pubmed/25966934>
7. Sinclair R. Treatment of monilethrix with oral minoxidil. *JAAD Case Rep*. 2016;2:212–5, <http://dx.doi.org/10.1016/j.jdcrr.2016.02.011>.
8. Liu L, Zhao S, Li F, Li E, Kang R, Luo L, et al. Effect of 5 α -reductase inhibitors on sexual function: A meta-analysis and systematic review of randomized controlled trials. *J Sex Med*. 2016, <http://dx.doi.org/10.1016/j.jsxm.2016.07.006>.
9. Seale LR, Eglini AN, McMichael AJ. Side effects related to 5 α -reductase inhibitor treatment of hair loss in women: A review. *J Drugs Dermatol*. 2016;15:414–9 [accessed 16 Ago 2016]. Available at: <http://www.ncbi.nlm.nih.gov/pubmed/27050696>
10. Chau CH, Price DK, Till C, Goodman PJ, Chen X, Leach RJ, et al. Finasteride concentrations and prostate cancer risk: Results from the Prostate Cancer Prevention Trial. *PLoS One*. 2015;10:e0126672, <http://dx.doi.org/10.1371/journal.pone.0126672>.
11. Duijnhoven RG, Straus SMJM, Souverein PC, de Boer A, Bosch JLHR, Hoes AW, et al. Long-term use of 5 α -reductase inhibitors and the risk of male breast cancer. *Cancer Causes Control*. 2014;25:1577–82, <http://dx.doi.org/10.1007/s10552-014-0455-6>.
12. Gupta AK, Charrette A. The efficacy and safety of 5 α -reductase inhibitors in androgenetic alopecia: A network meta-analysis and benefit-risk assessment of finasteride and dutasteride. *J Dermatolog Treat*. 2014;25:156–61, <http://dx.doi.org/10.3109/09546634.2013.813011>.
13. Boersma IH, Oranje AP, Grimalt R, Iorizzo M, Piraccini BM, Verdonchot EH. The effectiveness of finasteride and dutasteride used for 3 years in women with androgenetic alopecia. *Indian J Dermatol Venereol Leprol*. 2014;80:521–5, <http://dx.doi.org/10.4103/0378-6323.144162>.
14. Shanshanwal SJS, Dhurat RS. Superiority of dutasteride over finasteride in hair regrowth and reversal of miniaturization in men with androgenetic alopecia: A randomized controlled open-label, evaluator-blinded study. *Indian J Dermatol Venereol Leprol*. 2017;83:47–54 [accessed 24 Ago 2016]. Available at: <http://www.ncbi.nlm.nih.gov/pubmed/27549867>
15. Jung JY, Yeon JH, Choi JW, Kwon SH, Kim BJ, Youn SW, et al. Effect of dutasteride 0.5 mg/d in men with androgenetic alopecia recalcitrant to finasteride. *Int J Dermatol*. 2014;53:1351–7, <http://dx.doi.org/10.1111/ijd.12060>.
16. Gubelin Harcha W, Barboza Martínez J, Tsai T-F, Katsuoka K, Kawashima M, Tsuboi R, et al. A randomized, active- and placebo-controlled study of the efficacy and safety of different doses of dutasteride versus placebo and finasteride in the treatment of male subjects with androgenetic

- alopecia. *J Am Acad Dermatol.* 2014;70:489–98.e3, <http://dx.doi.org/10.1016/j.jaad.2013.10.049>.
17. Tsunemi Y, Irisawa R, Yoshiie H, Brotherton B, Ito H, Tsuboi R, et al. Long-term safety and efficacy of dutasteride in the treatment of male patients with androgenetic alopecia. *J Dermatol.* 2016;43:1051–8, <http://dx.doi.org/10.1111/1346-8138.13310>.
 18. Moftah N, Moftah N, Abd-Elaziz G, Ahmed N, Hamed Y, Ghannam B, et al. Mesotherapy using dutasteride-containing preparation in treatment of female pattern hair loss: Photographic, morphometric and ultrastructural evaluation. *J Eur Acad Dermatol Venerol.* 2013;27:686–93, <http://dx.doi.org/10.1111/j.1468-3083.2012.04535.x>.
 19. Caserini M, Radicioni M, Leuratti C, Terragni E, Iorizzo M, Palmieri R. Effects of a novel finasteride 0.25% topical solution on scalp and serum dihydrotestosterone in healthy men with androgenetic alopecia. *Int J Clin Pharmacol Ther.* 2016;54:19–27, <http://dx.doi.org/10.5414/CP202467>.
 20. Caserini M, Radicioni M, Leuratti C, Annoni O, Palmieri R. A novel finasteride 0.25% topical solution for androgenetic alopecia: Pharmacokinetics and effects on plasma androgen levels in healthy male volunteers. *Int J Clin Pharmacol Ther.* 2014;52:842–9, <http://dx.doi.org/10.5414/CP202119>.
 21. Choi YM, Diehl J, Levins PC. Promising alternative clinical uses of prostaglandin F_{2α} analogs: Beyond the eyelashes. *J Am Acad Dermatol.* 2015;72:712–6, <http://dx.doi.org/10.1016/j.jaad.2014.10.012>.
 22. Blume-Peytavi U, Lönnfors S, Hillmann K, Garcia Bartels N. A randomized double-blind placebo-controlled pilot study to assess the efficacy of a 24-week topical treatment by latanoprost 0.1% on hair growth and pigmentation in healthy volunteers with androgenetic alopecia. *J Am Acad Dermatol.* 2012;66:794–800, <http://dx.doi.org/10.1016/j.jaad.2011.05.026>.
 23. Nieves A, Garza LA. Does prostaglandin D2 hold the cure to male pattern baldness? *Exp Dermatol.* 2014;23:224–7, <http://dx.doi.org/10.1111/exd.12348>.
 24. Valente Duarte de Sousa IC, Tosti A. New investigational drugs for androgenetic alopecia. *Expert Opin Investig Drugs.* 2013;22:573–89, <http://dx.doi.org/10.1517/13543784.2013.784743>.
 25. Garza LA, Liu Y, Yang Z, Alagesan B, Lawson JA, Norberg SM, et al. Prostaglandin D2 inhibits hair growth and is elevated in bald scalp of men with androgenetic alopecia. *Sci Transl Med.* 2012;4, <http://dx.doi.org/10.1126/scitranslmed.3003122>, 126ra34.
 26. Keaney T. Emerging therapies for androgenetic alopecia. *J Drugs Dermatol.* 2015;14:1036–40 [accessed 22 Ago 2016]. Available at: <http://www.ncbi.nlm.nih.gov/pubmed/26355625>
 27. Zarei M, Wikramanayake TC, Falto-Aizpurua L, Schachner LA, Jimenez JJ. Low level laser therapy and hair regrowth: An evidence-based review. *Lasers Med Sci.* 2016;31:363–71, <http://dx.doi.org/10.1007/s10103-015-1818-2>.
 28. Jimenez JJ, Wikramanayake TC, Bergfeld W, Hordinsky M, Hickman JG, Hamblin MR, et al. Efficacy and safety of a low-level laser device in the treatment of male and female pattern hair loss: A multicenter, randomized, sham device-controlled, double-blind study. *Am J Clin Dermatol.* 2014;15:115–27, <http://dx.doi.org/10.1007/s40257-013-0060-6>.
 29. Avci P, Gupta GK, Clark J, Wikonkal N, Hamblin MR. Low-level laser (light) therapy (LLLT) for treatment of hair loss. *Lasers Surg Med.* 2014;46:144–51, <http://dx.doi.org/10.1002/lsm.22170>.
 30. Kim H, Choi JW, Kim JY, Shin JW, Lee S-J, Huh C-H. Low-level light therapy for androgenetic alopecia: A 24-week, randomized, double-blind, sham device-controlled multicenter trial. *Dermatol Surg.* 2013;39:1177–83, <http://dx.doi.org/10.1111/dsu.12200>.
 31. Dhurat R, Sukesh M, Avhad G, Dandale A, Pal A, Pund P. A randomized evaluator blinded study of effect of microneedling in androgenetic alopecia: A pilot study. *Int J Trichology.* 2013;5:6–11, <http://dx.doi.org/10.4103/0974-7753.114700>.
 32. Dhurat R, Mathapati S. Response to microneedling treatment in men with androgenetic alopecia who failed to respond to conventional therapy. *Indian J Dermatol.* 2015;60:260–3, <http://dx.doi.org/10.4103/0019-5154.156361>.
 33. Gentile P, Garcovich S, Bielli A, Scioli MG, Orlandi A, Cervelli V, et al. The effect of platelet-rich plasma in hair regrowth: A randomized placebo-controlled trial. *Stem Cells Transl Med.* 2015;4:1317–23, <http://dx.doi.org/10.5966/sctm.2015-0107>.
 34. Gupta AK, Carviel JL. Meta-analysis of efficacy of platelet-rich plasma therapy for androgenetic alopecia. *J Dermatolog Treat.* 2016;1–4, <http://dx.doi.org/10.1080/09546634.2016.1179712>.
 35. Alves R, Grimalt R. Randomized placebo-controlled, double-blind half-head study to assess the efficacy of platelet-rich plasma on the treatment of androgenetic alopecia. *Dermatol Surg.* 2016;42:491–7, <http://dx.doi.org/10.1097/DSS.0000000000000665>.
 36. Tosti A, Zaiac MN, Canazza A, Sanchis-Gomar F, Pareja-Galeano H, Alis R, et al. Topical application of the Wnt/β-catenin activator methyl vanillate increases hair count and hair mass index in women with androgenetic alopecia. *J Cosmet Dermatol.* 2016, <http://dx.doi.org/10.1111/jocd.12225>.
 37. Jo SJ, Shin H, Park YW, Paik SH, Park WS, Jeong YS, et al. Topical valproic acid increases the hair count in male patients with androgenetic alopecia: A randomized, comparative, clinical feasibility study using phototrichogram analysis. *J Dermatol.* 2014;41:285–91, <http://dx.doi.org/10.1111/1346-8138.12422>.
 38. Yazici Y. Safety and efficacy of a topical treatment (SM04554) for androgenetic alopecia (AGA): Results from a phase 1 Trial. *J Am Acad Dermatol.* 2016;74:AB138, <http://dx.doi.org/10.1016/j.jaad.2016.02.544>.
 39. Deng Z, Lei X, Zhang X, Zhang H, Liu S, Chen Q, et al. mTOR signaling promotes stem cell activation via counterbalancing BMP-mediated suppression during hair regeneration. *J Mol Cell Biol.* 2015;7:62–72, <http://dx.doi.org/10.1093/jmcb/mjv005>.
 40. Harel S, Higgins CA, Cerise JE, Dai Z, Chen JC, Clynes R, et al. Pharmacologic inhibition of JAK-STAT signaling promotes hair growth. *Sci Adv.* 2015;1:e1500973, <http://dx.doi.org/10.1126/sciadv.1500973>.
 41. Carrasco E, Calvo MI, Blázquez-Castro A, Vecchio D, Zamarrón A, de Almeida IJD, et al. Photoactivation of ROS production in situ transiently activates cell proliferation in mouse skin and in the hair follicle stem cell niche promoting hair growth and wound healing. *J Invest Dermatol.* 2015;135:2611–22, <http://dx.doi.org/10.1038/jid.2015.248>.
 42. McElwee KJ, Kissling S, Wenzel E, Huth A, Hoffmann R. Cultured peribulbar dermal sheath cells can induce hair follicle development and contribute to the dermal sheath and dermal papilla. *J Invest Dermatol.* 2003;121:1267–75, <http://dx.doi.org/10.1111/j.1523-1747.2003.12568.x>.
 43. Shin H, Ryu HH, Kwon O, Park B-S, Jo SJ. Clinical use of conditioned media of adipose tissue-derived stem cells in female pattern hair loss: A retrospective case series study. *Int J Dermatol.* 2015;54:730–5, <http://dx.doi.org/10.1111/ijd.12650>.
 44. Fukuoka H, Suga H. Hair regeneration treatment using adipose-derived stem cell conditioned medium: Follow-up with trichograms. *Eplasty.* 2015;15:e10 [accessed 16 Ago 2016]. Available at: <http://www.ncbi.nlm.nih.gov/pubmed/25834689>
 45. Zhang P, Kling RE, Ravuri SK, Kokai LE, Rubin JP, Chai J-K, et al. A review of adipocyte lineage cells and dermal papilla cells in hair follicle regeneration. *J Tissue Eng.* 2014;5, <http://dx.doi.org/10.1177/2041731414556850>, 2041731414556850.

46. Lamb RC, Young D, Holmes S. Retrospective review of diphen-cyprone in the treatment of alopecia areata. *Clin Exp Dermatol*. 2016;41:352–8, <http://dx.doi.org/10.1111/ced.12776>.
47. Shreberk-Hassidim R, Ramot Y, Gilula Z, Zlotogorski A. A systematic review of pulse steroid therapy for alopecia areata. *J Am Acad Dermatol*. 2016;74:372e1–4e5, <http://dx.doi.org/10.1016/j.jaad.2015.09.045>.
48. Vaño Galván S, Hermosa-Gelbard Á, Sánchez-Neila N, Miguel-Gómez L, Saceda-Corralo D, Rodrigues-Barata R, et al. Pulse corticosteroid therapy with oral dexamethasone for the treatment of adult alopecia totalis and universalis. *J Am Acad Dermatol*. 2016;74:1005–7, <http://dx.doi.org/10.1016/j.jaad.2015.12.026>.
49. Lattouf C, Jimenez JJ, Tosti A, Miteva M, Wikramanayake TC, Kittles C, et al. Treatment of alopecia areata with simvastatin/ezetimibe. *J Am Acad Dermatol*. 2015;72:359–61, <http://dx.doi.org/10.1016/j.jaad.2014.11.006>.
50. Loi C, Starace M, Piraccini BM. Alopecia areata (AA) and treatment with simvastatin/ezetimibe: Experience of 20 patients. *J Am Acad Dermatol*. 2016;74:e99–100, <http://dx.doi.org/10.1016/j.jaad.2015.09.071>.
51. Xing L, Dai Z, Jabbari A, Cerise JE, Higgins CA, Gong W, et al. Alopecia areata is driven by cytotoxic T lymphocytes and is reversed by JAK inhibition. *Nat Med*. 2014;20:1043–9, <http://dx.doi.org/10.1038/nm.3645>.
52. Craiglow BG, Tavares D, King BA. Topical ruxolitinib for the treatment of alopecia universalis. *JAMA Dermatol*. 2016;152:490–1, <http://dx.doi.org/10.1001/jamadermatol.2015.4445>.
53. Jabbari A, Dai Z, Xing L, Cerise JE, Ramot Y, Berkun Y, et al. Reversal of alopecia areata following treatment with the JAK1/2 inhibitor baricitinib. *EBioMedicine*. 2015;2:351–5, <http://dx.doi.org/10.1016/j.ebiom.2015.02.015>.
54. Harris JE, Rashighi M, Nguyen N, Jabbari A, Ulerio G, Clynes R, et al. Rapid skin repigmentation on oral ruxolitinib in a patient with coexistent vitiligo and alopecia areata (AA). *J Am Acad Dermatol*. 2016;74:370–1, <http://dx.doi.org/10.1016/j.jaad.2015.09.073>.
55. Jabbari A, Nguyen N, Cerise JE, Ulerio G, de Jong A, Clynes R, et al. Treatment of an alopecia areata patient with tofacitinib results in regrowth of hair and changes in serum and skin biomarkers. *Exp Dermatol*. 2016;25:642–3, <http://dx.doi.org/10.1111/exd.13060>.
56. Mrowietz U, Gerdes S, Gläser R, Schröder O. Successful treatment of refractory alopecia areata universalis and psoriatic arthritis, but not of plaque psoriasis with tofacitinib in a young woman. *Acta Derm Venereol*. 2016, <http://dx.doi.org/10.2340/00015555-2491>.
57. Gupta AK, Carviel JL, Abramovits W. Efficacy of tofacitinib in treatment of alopecia universalis in two patients. *J Eur Acad Dermatol Venereol*. 2016;30:1373–8, <http://dx.doi.org/10.1111/jdv.13598>.
58. Anzengruber F, Maul J-T, Kamarachev J, Trüeb RM, French LE, Navarini AA. Transient efficacy of tofacitinib in alopecia areata universalis. *Case Rep Dermatol*. 2016;8:102–6, <http://dx.doi.org/10.1159/000445182>.
59. Vaño-Galván S, Molina-Ruiz AM, Serrano-Falcón C, Arias-Santiago S, Rodrigues-Barata AR, Garnacho-Saucedo G, et al. Frontal fibrosing alopecia: A multicenter review of 355 patients. *J Am Acad Dermatol*. 2014;70:670–8, <http://dx.doi.org/10.1016/j.jaad.2013.12.003>.
60. Ladziński B, Bazakas A, Selim MA, Olsen EA. Frontal fibrosing alopecia: A retrospective review of 19 patients seen at Duke University. *J Am Acad Dermatol*. 2013;68:749–55, <http://dx.doi.org/10.1016/j.jaad.2012.09.043>.
61. Vaño-Galván S, Saceda-Corral D, Alonso-Castro L, Urech M, Espada J. Antiandrogenic drugs, a therapeutic option for frontal fibrosing alopecia patients. *J Am Acad Dermatol*. 2016;74:e77, <http://dx.doi.org/10.1016/j.jaad.2015.11.047>.
62. Harries MJ, Messenger A. Treatment of frontal fibrosing alopecia and lichen planopilaris. *J Eur Acad Dermatol Venereol*. 2014;28:1404–5, <http://dx.doi.org/10.1111/jdv.12362>.
63. Martínez-Pérez M, Churrua-Grijelmo M. Frontal fibrosing alopecia: An update on epidemiology and treatment. *Actas Dermosifiliogr*. 2015;106:757–8, <http://dx.doi.org/10.1016/j.ad.2014.12.002>.
64. Donovan JC. Finasteride-mediated hair regrowth and reversal of atrophy in a patient with frontal fibrosing alopecia. *JAAD Case Rep*. 2015;1:353–5, <http://dx.doi.org/10.1016/j.jdcrc.2015.08.003>.
65. Tziotzios C, Fenton DA, Stefanato CM, McGrath JA. Finasteride is of uncertain utility in treating frontal fibrosing alopecia. *J Am Acad Dermatol*. 2016;74:e73–4, <http://dx.doi.org/10.1016/j.jaad.2015.09.076>.
66. Karnik P, Tekeste Z, McCormick TS, Gilliam AC, Price VH, Cooper KD, et al. Hair follicle stem cell-specific PPARgamma deletion causes scarring alopecia. *J Invest Dermatol*. 2009;129:1243–57, <http://dx.doi.org/10.1038/jid.2008.369>.
67. Spring P, Spanou Z, de Viragh PA. Lichen planopilaris treated by the peroxisome proliferator activated receptor-γ agonist pioglitazone: Lack of lasting improvement or cure in the majority of patients. *J Am Acad Dermatol*. 2013;69:830–2, <http://dx.doi.org/10.1016/j.jaad.2013.04.066>.
68. Mesinkovska NA, Tellez A, Dawes D, Piliang M, Bergfeld W. The use of oral pioglitazone in the treatment of lichen planopilaris. *J Am Acad Dermatol*. 2015;72:355–6, <http://dx.doi.org/10.1016/j.jaad.2014.10.036>.
69. Mirmirani P, Karnik P. Lichen planopilaris treated with a peroxisome proliferator-activated receptor gamma agonist. *Arch Dermatol*. 2009;145:1363–6, <http://dx.doi.org/10.1001/archdermatol.2009.283>.
70. Baibergenova A, Walsh S. Use of pioglitazone in patients with lichen planopilaris. *J Cutan Med Surg*. 2012;16:97–100, <http://dx.doi.org/10.2310/7750.2011.11008>.
71. Márquez-García A, Camacho FM. Tratamiento de la alopecia frontal fibrosante: pioglitazonas. *Monogr Dermatol*. 2016;29:66–76.
72. Vaño-Galván S, Molina-Ruiz AM, Fernández-Crehuet P, Rodrigues-Barata AR, Arias-Santiago S, Serrano-Falcón C, et al. Folliculitis decalvans: A multicentre review of 82 patients. *J Eur Acad Dermatol Venereol*. 2015;29:1750–7, <http://dx.doi.org/10.1111/jdv.12993>.
73. Miguel-Gomez L, Vano-Galvan S, Perez-Garcia B, Carrillo-Gijon R, Jaen-Olasolo P. Treatment of folliculitis decalvans with photodynamic therapy: Results in 10 patients. *J Am Acad Dermatol*. 2015;72:1085–7, <http://dx.doi.org/10.1016/j.jaad.2015.02.1120>.
74. Burillo-Martinez S, Maroñas-Jimenez L, Palencia-Pérez SI, Vanaclocha-Sebastián F, López-Gómez S. Failure of photodynamic therapy (PDT) in 3 patients with folliculitis decalvans. *J Am Acad Dermatol*. 2016;74:e69–70, <http://dx.doi.org/10.1016/j.jaad.2015.09.075>.
75. Avram MR, Watkins SA. Robotic follicular unit extraction in hair transplantation. *Dermatol Surg*. 2014;40:1319–27, <http://dx.doi.org/10.1097/DSS.000000000000191>.
76. Gho CG, Neumann HAM. Advances in hair transplantation: Longitudinal partial follicular unit transplantation. *Curr Probl Dermatol*. 2015;47:150–7, <http://dx.doi.org/10.1159/000369416>.